



UNIVERSITY
OF WOLLONGONG
AUSTRALIA

University of Wollongong
Research Online

Faculty of Science, Medicine and Health - Papers

Faculty of Science, Medicine and Health

2013

Coblation-assisted Lewis and MacKay operation (CobLAMO): new technique for tongue reduction in sleep apnoea surgery

Stuart Mackay

University of Wollongong, stuartma@uow.edu.au

N Jefferson

Wollongong Hospital

L Grundy

Wollongong Hospital

R Lewis

Royal Perth Hospital

Publication Details

Mackay, S. G., Jefferson, N., Grundy, L. & Lewis, R. (2013). Coblation-assisted Lewis and MacKay operation (CobLAMO): new technique for tongue reduction in sleep apnoea surgery. *Journal of Laryngology and Otology*, 127 (12), 1222-1225.

Research Online is the open access institutional repository for the University of Wollongong. For further information contact the UOW Library:
research-pubs@uow.edu.au

Coblation-assisted Lewis and MacKay operation (CobLAMO): new technique for tongue reduction in sleep apnoea surgery

Abstract

Background: Obstructive sleep apnoea is a common condition that is unfortunately associated with a high rate of patient non-compliance regarding device use. Newer surgical interventions have focused on procedures at the palate level, using variants of palatoplasty and transpalatal advancement. However, the extent of tongue reduction surgery required remains controversial. The authors propose an in-between variant that combines midline glossectomy resection (with minimal mucosal sacrifice) and lateral coblation tongue channelling. **Method:** Four patients underwent a coblation-assisted Lewis and MacKay operation, which is a new technique for tongue reduction. This involved a midline glossectomy combined with lateral coblation channelling of the tongue, alone or as part of major airway reconstruction. Demographic, polysomnographic and quality of life questionnaire data were collected prospectively and analysed. **Results and conclusion:** No significant complications were noted in the four patients. (Results of the post-surgical outcomes are presented in another paper.) The coblation-assisted Lewis and MacKay operation reduced the potential complications of aggressive tongue surgery. The contours of the tongue were maintained, but significant reduction was still achieved.

Keywords

tongue, coblation, assisted, lewis, mackay, reduction, operation, sleep, coblamo, surgery, technique, apnoea

Disciplines

Medicine and Health Sciences | Social and Behavioral Sciences

Publication Details

Mackay, S. G., Jefferson, N., Grundy, L. & Lewis, R. (2013). Coblation-assisted Lewis and MacKay operation (CobLAMO): new technique for tongue reduction in sleep apnoea surgery. *Journal of Laryngology and Otology*, 127 (12), 1222-1225.

Coblation-assisted Lewis and MacKay operation (CobLAMO): new technique for tongue reduction in sleep apnoea surgery

S G MACKAY^{1,2}, N JEFFERSON¹, L GRUNDY³, R LEWIS⁴

¹Department of Otolaryngology Head Neck Surgery, The Wollongong Hospital, ²Graduate School of Medicine, University of Wollongong, ³Department of Anaesthesia, The Wollongong Hospital, and ⁴Department of Otolaryngology Head and Neck Surgery, Royal Perth Hospital, Australia

Abstract

Background: Obstructive sleep apnoea is a common condition that is unfortunately associated with a high rate of patient non-compliance regarding device use. Newer surgical interventions have focused on procedures at the palate level, using variants of palatoplasty and transpalatal advancement. However, the extent of tongue reduction surgery required remains controversial. The authors propose an in-between variant that combines midline glossectomy resection (with minimal mucosal sacrifice) and lateral coblation tongue channelling.

Method: Four patients underwent a coblation-assisted Lewis and MacKay operation, which is a new technique for tongue reduction. This involved a midline glossectomy combined with lateral coblation channelling of the tongue, alone or as part of major airway reconstruction. Demographic, polysomnographic and quality of life questionnaire data were collected prospectively and analysed.

Results and conclusion: No significant complications were noted in the four patients. (Results of the post-surgical outcomes are presented in another paper.) The coblation-assisted Lewis and MacKay operation reduced the potential complications of aggressive tongue surgery. The contours of the tongue were maintained, but significant reduction was still achieved.

Key words: Obstructive Sleep Apnea; Quality of Life; Questionnaires; Snoring; Reconstructive Surgical Procedures

Introduction

Obstructive sleep apnoea (OSA) is a common condition that is unfortunately associated with a high rate of patient non-compliance regarding device use, particularly concerning the use of the continuous positive airway pressure device and, less so, the mandibular advancement splint.¹

Newer surgical interventions at the palate level have focused on lateral velopharyngeal port opening with modified variants of uvulopalatopharyngoplasty,² anterior advancement using variants of palatoplasty and transpalatal advancement.³ However, the extent of tongue reduction surgery required remains controversial.

Some proponents support more conservative tongue reduction techniques involving radiofrequency or coblation tongue channelling,⁴ whilst others utilise more aggressive techniques, such as submucosal lingualplasty.⁵ The authors of this paper propose an in-between variant that combines midline glossectomy resection (with minimal mucosal sacrifice) and lateral coblation tongue channelling. To our knowledge, this is the first description of a tongue reduction technique involving resection and ablation.

Materials and methods

Ethics review board approval was obtained through the Ethics Unit, Research Services Office, at the University of Wollongong in Australia.

This study involves a cohort of patients who underwent major airway reconstruction surgery for OSA that went beyond modified uvulopalatopharyngoplasty; this cohort are described by the first and second authors in a different article.⁶ Within that cohort, four patients underwent a coblation-assisted Lewis and MacKay operation ('CobLAMO'). This is a new technique for tongue reduction, involving midline glossectomy combined with lateral coblation channelling of the tongue.

The steps involved in the coblation-assisted Lewis and MacKay operation are described below.

Pre-operative stage

Firstly, an arterial line was inserted for constant blood pressure monitoring (particularly mean arterial pressure). This was followed by nasal intubation, and the intravenous administration of antibiotics (cephalosporin 2 g and metronidazole 500 mg) and dexamethasone (8 mg for the standard adult).

Peri-operative stage

This step began with the infusion of dexmedetomidine. Functionally, the aim of this was to continue post-operatively the intraoperative blood pressure control that is achieved by general anaesthesia, and in particular, to avoid rebound

hypertension, which contributes to the risk of tongue oedema and airway obstruction with extubation.

Four-channel lateral coblation channelling of the tongue was performed using a ReFlex Ultra SP Plasma Wand (Arthrocare, Austin, Tennessee, USA), at a coblate power setting of 6, for 15 seconds per channel. Channels were created at the junction of the dorsal tongue mucosa and the lateral tongue mucosa in the axial plane by orientating

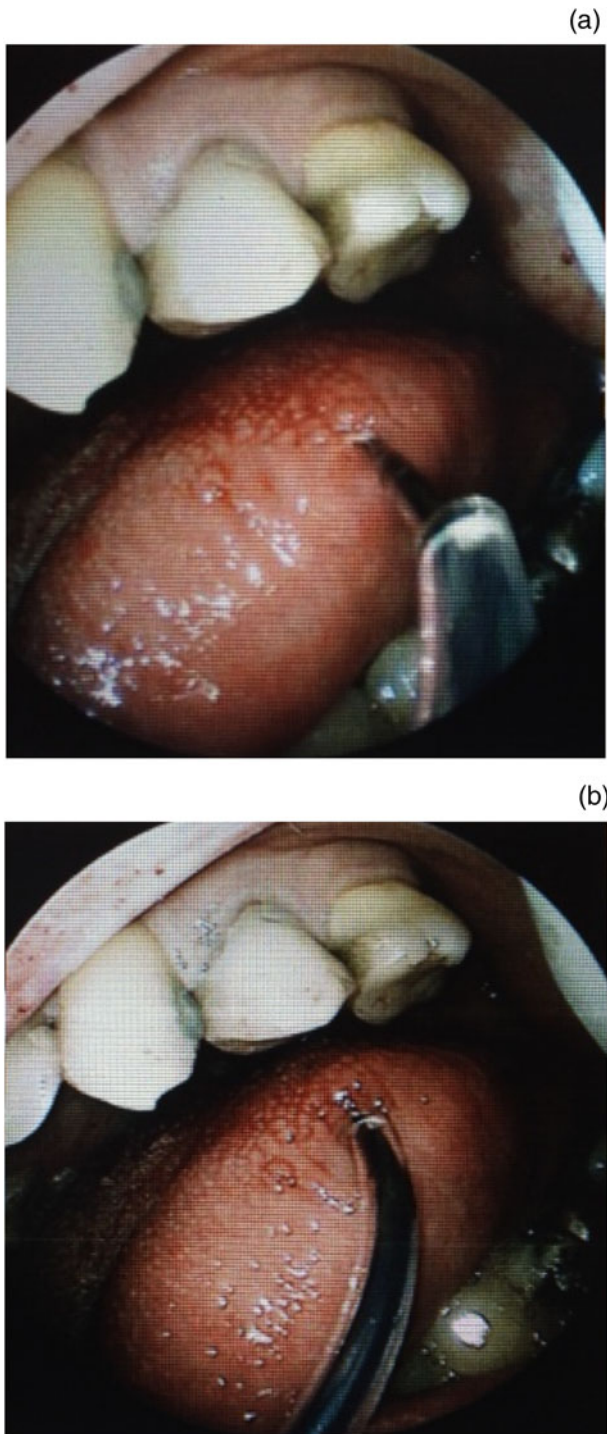


FIG. 1

Peri-operative view of coblation wand insertion into lateral tongue, showing (a) insertion point at the junction of the smooth and rough tongue surface mucosa, and (b) upward and posteriorly directed angulation of the instrument, to avoid the neurovascular bundle.

the wand in the direction of the circumvallate papillae or just posterior, with two channels on each side, spaced 1–1.5 cm apart (Figure 1).

Using needle point or protected tip diathermy (with a coagulation setting of 15), an elliptical excision of the tongue was carried out, which ran from the middle third of the tongue (in the midline) to the circumvallate papillae (Figure 2). The dissection was carried through the mucosa. Stay sutures were then introduced laterally (Figure 3).

Harmonic Focus curved shears (Ethicon Endo-Surgery (Johnson & Johnson), Piscataway, New Jersey, USA) were used (with the default settings 5 and 3) to resect a midline

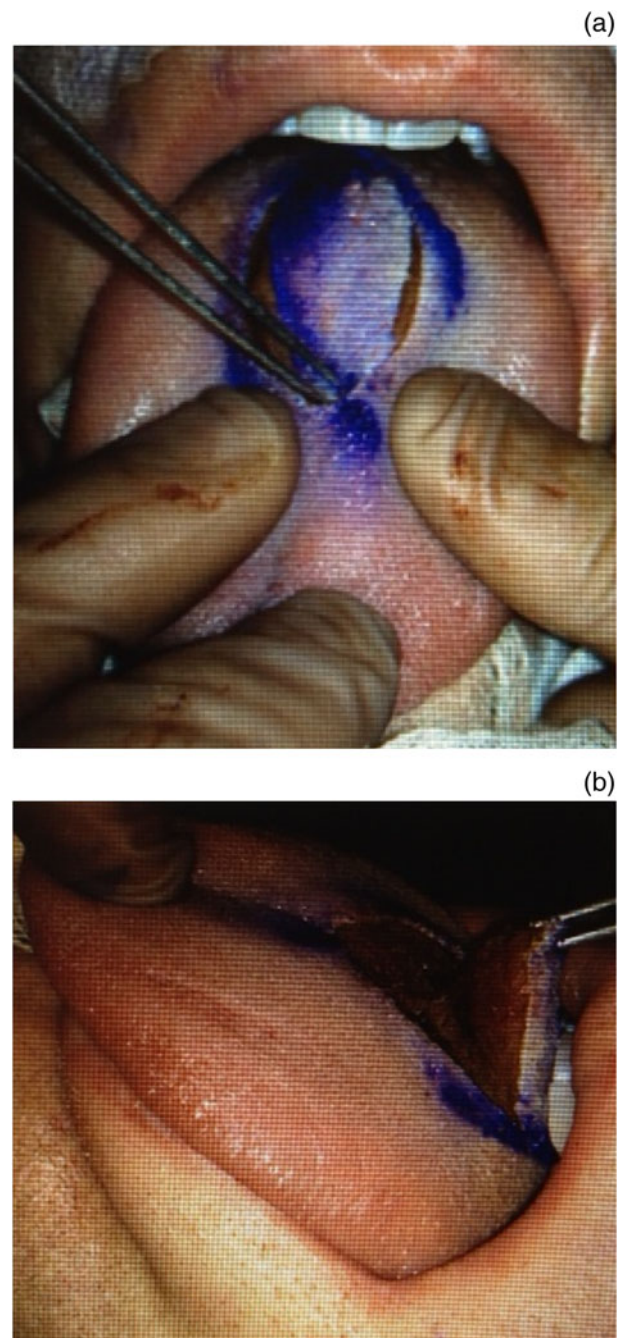


FIG. 2

Peri-operative view during midline glossectomy, showing (a) area marked for excision and (b) lateral perspective of the tissue during excision.

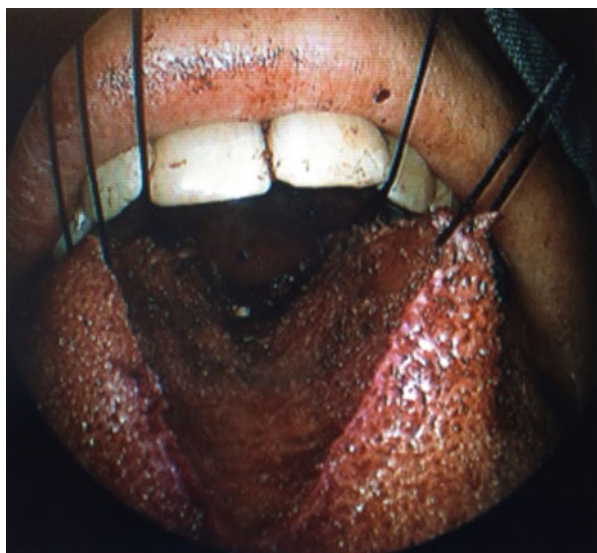

FIG. 3

Peri-operative view showing sutures used to mobilise tongue during posterior excision.

segment of tongue tissue. As the excision was carried posteriorly, further stay sutures were applied posteriorly and laterally (Figure 3). Around 8–12 ml of tongue tissue was safely resected; this resection extended caudally to the depth of the genioglossus muscle, laterally 5–10 mm either side of the midline and posteriorly as close to the posterior surface of the tongue mucosa as possible (to where a fingertip could palpate the epiglottis through the mucosa of the tongue).

After haemostasis had been achieved using bipolar diathermy or small Ligaclips® as required, the surgical wounds were closed. This involved the placement of: large size 0 Vicryl™ sutures, opposing the submucosal tissue; and smaller 2-0 Vicryl sutures that closed up the mucosa, leaving a small 1 cm defect in the mucosa posteriorly as a drainage hole. However, no drain was required.

Post-operative stage

Patients were extubated 4 hours post-operatively and were monitored in a high dependency setting. Strict monitoring of mean arterial pressure was required to keep it below 100 mmHg. This was followed by 24–48 hours of intravenous dexamethasone (8 mg twice daily) and antibiotics, and a subsequent 5–7 day course of oral antibiotics (cephalexin 500 mg four times daily).

Results

The data (demographic, body mass index, pre-operative and post-operative parameter, and questionnaire data) for the four patients who underwent the coblation-assisted Lewis and MacKay operation are shown in Table I. (Statistical analysis of these data is described in another paper.)⁶

No significant complications were noted in the four patients. One patient (patient 2) underwent successful repeat coblation channelling of the tongue (using three midline channels and a repeat with four lateral channels as described above). This was because of mild globus pharyngeus symptoms, which were presumed to be related to the proximity of an advanced free edge of the palate to the posterior third of the tongue.

TABLE I
PATIENT DATA

Pt no	Pt sex, age (y)	Procedure	Pre-operation				Post-operation			
			BMI (kg/m ²)	AHI	Lowest O ₂ sat	ESS	SSS	BMI (kg/m ²)	AHI	Lowest O ₂ sat
1	M, 39	CobLAMO	26.5	35.8	90	5	3	28.2	17.9	88
2	F, 57	TPA + mod UPPP + CobLAMO	26.6	37.3	88	11	8	26.9	11	89
3	M, 65	TPA + rev mod UPPP + CobLAMO	30.5	45.1	79	16	8	29.6	21	83
4	M, 51	TPA + mod UPPP + CobLAMO	26	38.4	80	9	6	27.5	4.2	84

Pt = patient number; no = number; y = years; BMI = body mass index; AHI = apnoea-hypopnoea index score (events per hour); O₂ sat = oxygen saturation level; ESS = Epworth sleepiness scale score; SSS = snoring severity score; M = male; CobLAMO = coblation-assisted Lewis and MacKay operation; NR = not recorded; F = female; TPA = transpalatal advancement; mod = modified; UPPP = uvulopalatopharyngoplasty; rev = revision

Discussion

Tongue reduction surgery for OSA is a complicated procedure. Surgeons have debated the extent of resection or reduction of the tongue required.

Clinical outcomes for this group of patients are discussed in another of our articles.⁶ We believe that the coblation-assisted Lewis and MacKay operation reduced the potential complications of aggressive tongue surgery, such as submucosal lingualplasty.⁵ The contours of the tongue were maintained, but significant reduction was still achieved.

This procedure involved both resection and ablation. Specifically, midline glossectomy was combined with lateral coblation channelling of the tongue. In coblation channelling, the ablation of tissue is achieved by creating an ionic field (generated by radiofrequency) in saline, which breaks the tissue down into low molecular weight gases.

This technique did not require imaging of the lateral neurovascular bundles prior to surgery, and allowed for further revision tongue reduction surgery if required.

It should be noted that the technique is performed by creating the lateral coblation channels first. This is so that the tongue architecture is not distorted prior to the creation of these channels, as might be the case if the midline glossectomy was performed first.

Conclusion

We believe the coblation-assisted Lewis and MacKay operation, which combines midline glossectomy and lateral coblation channelling of the tongue, affords excellent reduction of tongue size with minimal complication. However, this procedure has so far only been performed on a small number of patients. Future research might focus on the use of this technique in a larger number of patients and

the longevity of the results achieved, as well as any complication profile.

References

- 1 Weaver TE, Grunstein RR. Adherence to continuous positive airway pressure therapy: the challenge to effective treatment. *Proc Am Thorac Soc* 2008;**5**:173–8
- 2 Mackay SG, Carney AS, Woods C, Antic NA, McEvoy RD, Chia M *et al*. Modified uvulopalatopharyngoplasty and coblation channelling of the tongue for obstructive sleep apnea: a multi-centre Australian trial. *J Clin Sleep Med* 2013;**9**:117–24
- 3 Fairbanks DNF, Mickelson SA, Woodson BT. *Snoring and Obstructive Sleep Apnea*, 3rd edn. Philadelphia: Lippincott Williams and Williams, 2003;160–6
- 4 Zhang Q, Song W, She C, Liu D, Li D, Zhang X *et al*. Coblation-assisting uvulopalatopharyngoplasty combining coblation-channelling of the tongue for patients with severe OSAHS [in Chinese]. *Lin Chung Er Bi Yan Hou Tou Jing Wai Ke Za Zhi* 2012;**26**:114–17
- 5 Robinson S, Krishnan S, Hodge JC, Foreman A. Conventional tongue base volumetric reduction for obstructive sleep apnea. *Operative Techniques in Otolaryngology* 2012;**23**:36–44
- 6 MacKay SG, Jefferson ND, Marshall NS. Beyond uvulopalatopharyngoplasty for obstructive sleep apnoea: single surgeon case series of contemporary airway reconstruction. *J Laryngol Otol* In press

Address for correspondence:

A/Prof Stuart MacKay,
1–2, 8–10 Victoria St,
Wollongong, NSW,
Australia 2500

Fax: +61 2 4227 6292

E-mail: sgmackay@ozemail.com.au

Associate Prof S G MacKay takes responsibility for
the integrity of the content of the paper
Competing interests: None declared
