

University of Wollongong

Research Online

Faculty of Science, Medicine and Health -
Papers: part A

Faculty of Science, Medicine and Health

1-1-2008

Acinetobacter baumannii mediastinitis after cardiopulmonary bypass: case report and literature review

Elias Lachanas
University of Athens

Periklis Tomos
University of Athens

Nicolaos Sfyras
Ippokrateion Hospital

Spiros Miyakis
University of Athens, smiyakis@uow.edu.au

Alkiviadis Kostakis
University of Athens

Follow this and additional works at: <https://ro.uow.edu.au/smhpapers>



Part of the [Medicine and Health Sciences Commons](#), and the [Social and Behavioral Sciences Commons](#)

Recommended Citation

Lachanas, Elias; Tomos, Periklis; Sfyras, Nicolaos; Miyakis, Spiros; and Kostakis, Alkiviadis, "Acinetobacter baumannii mediastinitis after cardiopulmonary bypass: case report and literature review" (2008). *Faculty of Science, Medicine and Health - Papers: part A*. 222.
<https://ro.uow.edu.au/smhpapers/222>

Research Online is the open access institutional repository for the University of Wollongong. For further information contact the UOW Library: research-pubs@uow.edu.au

Acinetobacter baumannii mediastinitis after cardiopulmonary bypass: case report and literature review

Abstract

Background: Mediastinitis resulting from surgical site infection may occur in 1% of patients undergoing median sternotomy. Methods: Case report and review of the pertinent English-language literature.

Results: We report a case of mediastinitis caused by *Acinetobacter baumannii*, in a patient with multiple comorbidities who underwent cardiopulmonary bypass. Successful treatment consisted of surgical debridement, reconstruction, and ampicillin-sulbactam. Conclusions: *Acinetobacter baumannii* should be recognized as a potential causative agent of severe postoperative mediastinitis.

Disciplines

Medicine and Health Sciences | Social and Behavioral Sciences

Publication Details

Lachanas, E., Tomos, P., Sfyras, N., Miyakis, S. & Kostakis, A. (2008). *Acinetobacter baumannii* mediastinitis after cardiopulmonary bypass: case report and literature review. *Surgical Infections*, 9 (2), 201-204.

Acinetobacter baumannii Mediastinitis after Cardiopulmonary Bypass: Case Report and Literature Review

ELIAS LACHANAS,¹ PERIKLIS TOMOS,¹ NICOLAOS SFYRAS,²
SPIROS MIYAKIS,³ and ALKIVIADIS KOSTAKIS¹

ABSTRACT

Background: Mediastinitis resulting from surgical site infection may occur in 1% of patients undergoing median sternotomy.

Methods: Case report and review of the pertinent English-language literature.

Results: We report a case of mediastinitis caused by *Acinetobacter baumannii*, in a patient with multiple comorbidities who underwent cardiopulmonary bypass. Successful treatment consisted of surgical debridement, reconstruction, and ampicillin-sulbactam.

Conclusions: *Acinetobacter baumannii* should be recognized as a potential causative agent of severe postoperative mediastinitis.

ACINETOBACTER spp. are recognized increasingly as pathogens causing nosocomial infections, associated with considerable morbidity [1,2]. We report a patient with multiple risk factors who developed sternal osteomyelitis caused by *Acinetobacter baumannii* after cardiac surgery. Successful treatment consisted of surgical debridement, followed by reconstruction using the pectoralis muscles as flaps, combined with administration of ampicillin-sulbactam. We discuss the limited number of cases of mediastinitis caused by *Acinetobacter* spp. reported in the English-language literature. To the best of our knowledge, this is the first report of *A. baumannii* mediastinitis complicating cardiopulmonary bypass, underlying the idea that this nosocomial organism should be considered in the differential diagnosis of pathogens causing severe postoperative infections.

CASE REPORT

A 60-year-old obese (body mass index 34.6), diabetic, hypertensive female smoker underwent complete myocardial revascularization using the left internal mammary artery via median sternotomy. An intra-aortic balloon pump (IABP) inserted via the left femoral artery-supported her low cardiac index for 24 h postoperatively. The postoperative course was complicated by lower-extremity compartment syndrome, resulting in common peroneal nerve injury despite fasciotomy. The patient was discharged on postoperative day 20, otherwise well.

The patient was re-admitted two weeks post-discharge complaining of fever, sternal pain, and purulent discharge from the sternotomy scar. The admission temperature was 38.5°C,

¹2nd Propedeutic Department of Surgery, Athens University, Laikon Hospital, Athens, Greece.

²Department of Cardiac Surgery, Ippokrateion Hospital, Athens, Greece.

³3rd Department of Medicine, Athens University, Sotiria Hospital for Chest Diseases, Athens, Greece.

white blood cell count was $3,900/\text{mm}^3$ (89% neutrophils), C-reactive protein (CRP) concentration was 170 mg/L (normal $< 5 \text{ mg/L}$), and erythrocyte sedimentation rate (ESR) was 57 mm/h . The chest radiograph was normal. Computed tomography (CT) of the chest with three-dimensional reconstruction revealed extensive necrosis of the sternum (Fig. 1). There was no evidence of retrosternal space involvement. The patient was treated empirically with vancomycin for four days (until culture results were available) without improvement. Blood cultures were negative. Gram stain of pus from the sternal wound revealed non-motile gram-negative coccobacilli. The organisms were strictly aerobic, catalase-positive, and oxidase-negative. On culture (API 20NE system; Bio-Merieux API, Marcy l'Etoile, France), the isolate was identified as *Acinetobacter baumannii*, following the simplified identification scheme proposed [3]. Susceptibility testing with a broth

microdilution method performed and interpreted according to standard guidelines [4] revealed the following minimum inhibitory concentrations (MICs) (mcg/mL): ampicillin 16; ampicillin-sulbactam 1; piperacillin 16; ticarcillin-clavulanic acid 8; cefuroxime 32; cefotaxime 8; ceftazidime 2; cefepime 1; imipenem-cilastatin 0.5; gentamicin 1; amikacin 1; and ciprofloxacin 32.

The diagnosis was postoperative infectious mediastinitis type IIIB [5] caused by *Acinetobacter baumannii*, and ampicillin-sulbactam (3 g every 6 h) was administered intravenously. The patient underwent pulmonary function tests and dobutamine stress echocardiography, which revealed small airways disease, no signs of myocardial ischemia, and a left ventricular ejection fraction of 60%. Therefore, surgical debridement and sternum reconstruction was undertaken.

During the operation, wires and necrotic bone, cartilage, and soft tissue were removed,

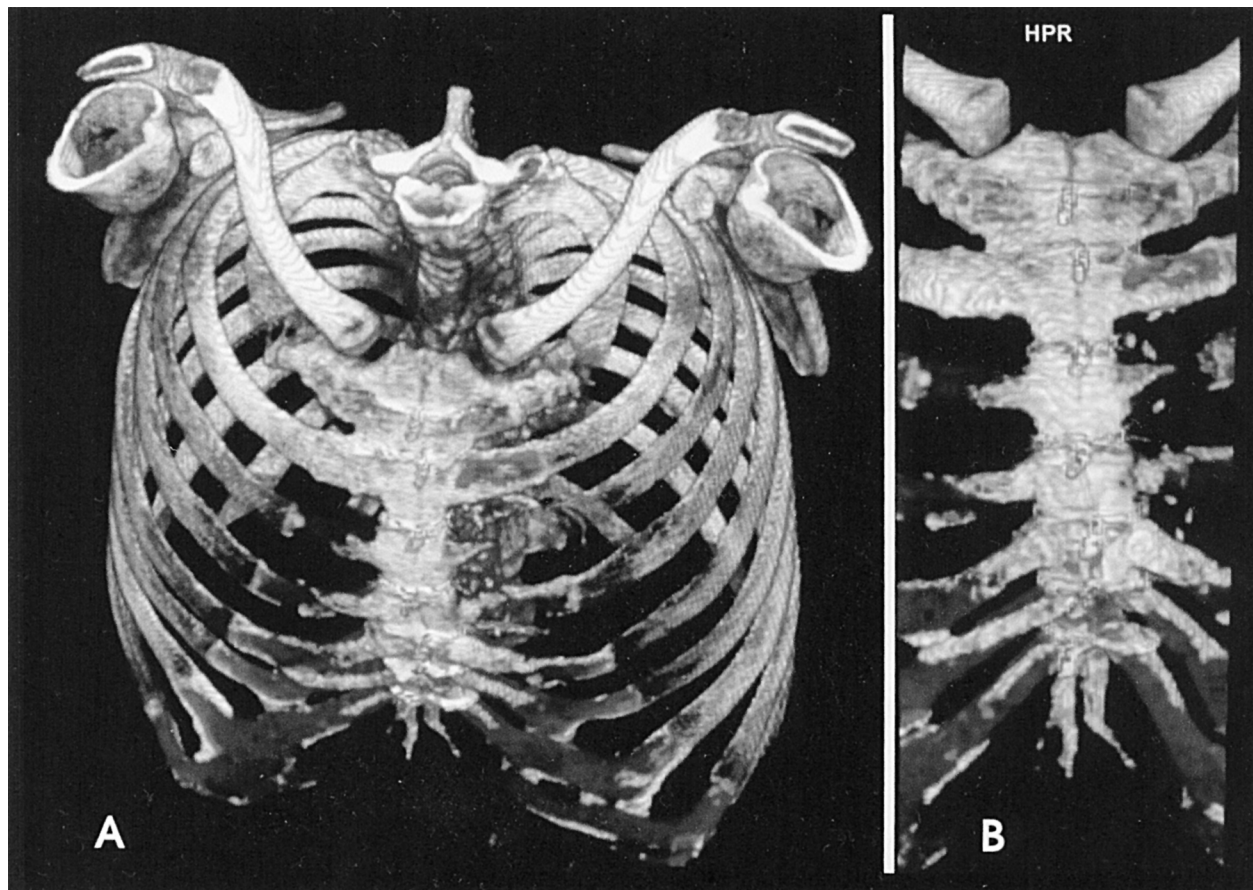


FIG. 1. Preoperative computed tomography scans of chest with three-dimensional reconstruction. (A) Thoracic cage. (B) Selected location in sternum, showing necrotic (dark) areas.

and the sternal defect was reconstructed using pectoral muscles as flaps [6]. Recovery was uneventful, and the patient was discharged on oral ampicillin-sulbactam on the tenth postoperative day in excellent physical condition, with a normal hematologic profile and sternal stability. *Acinetobacter baumannii* grew from culture of the necrotic bone, with an identical susceptibility pattern.

At follow-up three months later, the patient was free of symptoms, CRP and ESR were normal, and the surgical site was evaluated with a repeat three-dimensional CT scan and a three-phase ⁹⁹technetium methylene-diphosphonate scintigram, revealing normal healing and osteoblastic activity, respectively. Antibiotic treatment was then discontinued. The patient remains well; she ceased smoking, and her diabetes control is optimal.

DISCUSSION

Postoperative mediastinitis (surgical site infection associated with sternal osteomyelitis, with [organ/space] or without [deep incisional] infection of the retrosternal space) occurs in approximately 1% of patients undergoing median sternotomy for cardiopulmonary bypass [5]. The mortality rate is high (14%–48%), and the cost of hospitalization is increased [7,8]. Diabetes mellitus, obesity, tobacco smoking, airways disease, the use of the left internal mammary artery as a graft for cardiopulmonary bypass, and the use of an IABP are among the risk factors for mediastinitis after sternotomy [9]; all these risk factors were present in our patient.

Staphylococci (*Staphylococcus aureus*, *S. epidermidis*) are isolated in more than 70% of postoperative mediastinitis cases having an identifiable pathogen [10]. Mixed infections, including anaerobic species, may account for as many as 40% of cases [11]. The extent of the involvement of anaerobes in mediastinal infections still is debated; growth of these organisms in vitro is often laborious, whereas distinguishing anaerobes as true pathogens from commensal organisms is sometimes problematic [12]. Gram-negative organisms and fungi are infrequent isolates in mediastinal surgical site infections [10,11].

Acinetobacter baumannii is one of at least 21 *Acinetobacter* species. In clinical practice, genospecies 1 (*A. calcoaceticus*), 2 (*A. baumannii*), 3, and 13 are called *Acinetobacter baumannii-calcoaceticus* complex, representing approximately 80% of isolates from clinical infections [13]. In contrast with earlier beliefs (that *A. baumannii* opportunistically affected patients at high mortality risk), this organism is now an established pathogen of hospital infections, associated independently with a higher mortality rate [1,2]. *Acinetobacter* spp. most often cause ventilator-associated pneumonia, but may also cause blood stream infections, as well as other infections, such as intra-abdominal abscess, keratitis, and meningitis [1,14]. *Acinetobacter* mediastinitis is rare. A case of postoperative mediastinal infection caused by *A. calcoaceticus* has been reported in a patient with esophago-tracheal fistula [15], and a case of *A. baumannii* (then termed *A. anitratus*) sternoclavicular septic arthritis has been associated with intravenous drug abuse [16]. To our knowledge, the case described here is the first reported in the English-language literature of mediastinal wound infection caused by *A. baumannii* after cardiopulmonary bypass. Interestingly, the first case of multi-drug-resistant *A. baumannii* mediastinitis after heart transplantation has been described recently [17], identifying this organism as an emerging pathogen for postoperative infections.

Hospital-acquired infections caused by *Acinetobacter* spp. resistant to most broad-spectrum agents (with the usual exception of carbapenems and polymyxins) are encountered frequently worldwide [14], including our country [18]. The frequency of isolation and the susceptibility pattern of resistant isolates depends on local factors, such as infection control measures and local antibiotic use policies [14]. Antibiotic combinations have been given for multi-drug-resistant strains, with inconsistent outcomes [13]. The strain isolated from the present case was not multi-drug-resistant, and ampicillin-sulbactam was used. Sulbactam is active against *Acinetobacter* (i.e., in comparison with clavulanate and tazobactam), presumably because of the selective affinity to its penicillin binding proteins and more favorable pharmacokinetics [19]. Ampicillin-sulbactam in high

doses may be considered for the treatment of multi-drug-resistant strains if imipenem-cilastatin cannot be used or is contraindicated [13,19].

The optimal surgical treatment of mediastinal infections is debatable, and depends largely on the extent of tissue damage at the time of diagnosis [5,10]. When the diagnosis of sternal infection is delayed more than 20 days, optimal surgical treatment consists of prompt debridement followed by muscle flaps [10]; the latter procedure can be performed using the pectoralis muscles [5,6]. In addition to surgery, antibiotics should be administered; in cases with unidentified pathogens or in mixed infections, the drugs are directed against a broad spectrum of suspected pathogens, taking into account local patterns of resistance of the most common pathogens.

ACKNOWLEDGMENT

The authors thank Ms. Danielle Bowler for editing the manuscript.

REFERENCES

- Goh BK, Alkouder G, Lama TK, et al. Multi-drug-resistant *Acinetobacter baumannii* intra-abdominal abscess. *Surg Infect* 2005;6:345–347.
- Robenshtok E, Paul M, Leibovici L, et al. The significance of *Acinetobacter baumannii* bacteraemia compared with *Klebsiella pneumoniae* bacteraemia: Risk factors and outcomes. *J Hosp Infect* 2006;64:282–287.
- Bouvet PJ, Grimont PA. Identification and biotyping of clinical isolates of *Acinetobacter*. *Ann Inst Pasteur Microbiol* 1987;138:569–578.
- National Committee for Clinical Laboratory Standards. Methods for dilution antimicrobial susceptibility tests for bacteria that grow aerobically. Fourth edition. Approved Standard M7-A4. Wayne, PA. 1997.
- El Oakley RM, Wright JE. Postoperative mediastinitis: Classification and management. *Ann Thorac Surg* 1996;61:1030–1036.
- Tomos P, Lachanas E, Michail PO, et al. Alternative bi-pectoral muscle flaps for postoperative sternotomy mediastinitis. *Ann Thorac Surg* 2006;81:754–755.
- Loop FD, Lytle BW, Cosgrove DM, et al. Sternal wound complications after isolated coronary artery bypass grafting: Early and late mortality, morbidity and cost of care. *Ann Surg* 1990;49:179–187.
- Nelson RM, Dries DJ. The economic implications of infection in cardiac surgery. *Ann Thorac Surg* 1986;42:240–242.
- Demmy TL, Park SB, Liebler GA, et al. Recent experience with major sternal wound complications. *Ann Thorac Surg* 1990;49:458–462.
- Grossi EA, Culliford AT, Krieger KH, et al. A survey of 77 major infectious complications of median sternotomy: A review of 7,949 consecutive operative procedures. *Ann Thorac Surg* 1985;40:214–223.
- Sarr MG, Gott VL, Townsend TR. Mediastinal infection after cardiac surgery. *Ann Thorac Surg* 1984;38:415–426.
- Citron DM. Specimen collection and transport, anaerobic culture techniques, and identification of anaerobes. *Rev Infect Dis* 1984;6 Suppl 1:S51–S58.
- Murray CK, Hospenthal DR. Treatment of multidrug resistant *Acinetobacter*. *Curr Opin Infect Dis* 2005;18:502–506.
- Bergogne-Berezin E, Towner KJ. *Acinetobacter* spp. as nosocomial pathogens: Microbiological, clinical, and epidemiological features. *Clin Microbiol Rev* 1996;9:148–165.
- Stoutenbeek CP, van Saene HK, Miranda DR, et al. *Acinetobacter* mediastinitis and pneumonia in a thorotrastoma patient: The oropharyngeal flora as source of infection. *Intensive Care Med* 1983;9:139–141.
- Bayer AS, Chow AW, Louie JS, et al. Sternoarticular pyoarthrosis due to gram-negative bacilli: Report of eight cases. *Arch Intern Med* 1977;137:1036–1040.
- George RS, Birks EJ, Haj-Yahia S, et al. *Acinetobacter* mediastinitis in a heart transplant patient. *Ann Thorac Surg* 2006;82:715–716.
- Maniatis AN, Pournaras S, Orkopoulou S, et al. Multiresistant *Acinetobacter baumannii* isolates in intensive care units in Greece. *Clin Microbiol Infect* 2003;9:547–553.
- Marques MB, Brookings ES, Moser SA, et al. Comparative in vitro antimicrobial susceptibilities of nosocomial isolates of *Acinetobacter baumannii* and synergistic activities of nine antimicrobial combinations. *Antimicrob Agents Chemother* 1997;41:881–885.

Address reprint requests to:
 Dr. Spiros Miyakis
 3rd Department of Medicine
 Athens University
 Sotiria Hospital for Chest Diseases
 Mesogeion 152
 11527, Athens, Greece

E-mail: miyakis@hotmail.com