

University of Wollongong

## Research Online

---

Faculty of Health and Behavioural Sciences -  
Papers (Archive)

Faculty of Science, Medicine and Health

---

1-1-2012

### Organization of brainstem nuclei

George Paxinos

*University Of New South Wales, Neuroscience Research Australia*

Xu-Feng Huang

*University of Wollongong, xhuang@uow.edu.au*

Gulgun Sengul

*Ege University*

Charles Watson

*Curtin University, Neuroscience Research Australia*

Follow this and additional works at: <https://ro.uow.edu.au/hbspapers>



Part of the [Arts and Humanities Commons](#), [Life Sciences Commons](#), [Medicine and Health Sciences Commons](#), and the [Social and Behavioral Sciences Commons](#)

---

#### Recommended Citation

Paxinos, George; Huang, Xu-Feng; Sengul, Gulgun; and Watson, Charles: Organization of brainstem nuclei 2012, 260-327.

<https://ro.uow.edu.au/hbspapers/3056>

Research Online is the open access institutional repository for the University of Wollongong. For further information contact the UOW Library: [research-pubs@uow.edu.au](mailto:research-pubs@uow.edu.au)

---

## Organization of brainstem nuclei

### Abstract

This chapter describes human homologs of nuclei identified in the brainstem of other mammals and attempts to extend to the human the overall organizational schemata that have been proposed for the brainstem of other mammalian species. We present herein updated diagrams of the Atlas of the Human Brainstem (Paxinos and Huang, 1995). The diagrams have been thoroughly revised in light of our recent work on the rat (Paxinos and Watson, 2007) and rhesus monkey (Paxinos et al., 3rd ed, in BrainNavigator, Elsevier, 2010) as well as our work on the marmoset (Atlas of the Marmoset Brain in Stereotaxic Coordinates, Paxinos et al., (2012)).

### Keywords

organization, nuclei, brainstem

### Disciplines

Arts and Humanities | Life Sciences | Medicine and Health Sciences | Social and Behavioral Sciences

### Publication Details

Paxinos, G., Huang, X., Sengul, G. & Watson, C. (2012). Organization of brainstem nuclei. The Human Nervous System (pp. 260-327). Amsterdam: Elsevier Academic Press.

# Organization of Brainstem Nuclei

George Paxinos<sup>1,2</sup>, Huang Xu-Feng<sup>3</sup>, Gulgun Sengul<sup>4</sup>, Charles Watson<sup>1,5</sup>

<sup>1</sup>Neuroscience Research Australia, Sydney, Australia, <sup>2</sup>The University of New South Wales, Sydney, Australia,

<sup>3</sup>University of Wollongong, Wollongong, Australia, <sup>4</sup>Ege University, School of Medicine, Department of Anatomy, Bornova, Izmir, Turkey, <sup>5</sup>Faculty of Health Sciences, Curtin University, Perth, Australia

## OUTLINE

|   |     |  |     |
|---|-----|--|-----|
| <b>Abbreviations Used in the Figures</b>  | 262 | <b>Locus Coeruleus</b>   | 309 |
| <b>Autonomic Regulatory Centers</b>   | 300 | <i>Epicoeruleus Nucleus</i>                                      | 310 |
| <i>Dorsal Motor Nucleus of Vagus</i>  | 300 | <b>Raphe Nuclei</b>  | 310 |
| <i>Solitary Nucleus</i>   | 300 | <i>Raphe Obscurus and Magnus Nuclei</i>                          | 310 |
| <i>Parabrachial Nuclei</i>  | 302 | <i>Median and Paramedian Raphe Nuclei</i>                        | 311 |
| <i>Periaqueductal Gray</i>  | 303 | <i>Raphe Pontis Nucleus</i>                                      | 311 |
| <b>Reticular Formation</b>  | 304 | <i>Dorsal Raphe Nucleus</i>                                      | 311 |
| <i>Intermediate Reticular Zone</i>  | 304 | <b>Ventral Mesencephalic Tegmentum and Substantia Nigra</b>      | 312 |
| Historical Considerations   | 304 | <i>Caudal Linear Nucleus</i>                                     | 312 |
| Position  | 304 | <i>Interfascicular Nucleus</i>                                   | 312 |
| Catecholamine Cells   | 304 | <i>Rostral Linear Nucleus</i>                                    | 312 |
| Neuropeptide Y  | 305 | <i>Retrobulbar Fields</i>  | 312 |
| Serotonin   | 305 | <i>Paranigral Nucleus</i>  | 312 |
| Substance P   | 305 | <i>Parabrachial Pigmented Nucleus</i>                            | 312 |
| Salmon Calcitonin-Binding Sites   | 305 | <i>Substantia Nigra</i>  | 312 |
| Connections   | 305 | <i>Interpeduncular Nucleus</i>                                   | 313 |
| <i>Retroambiguus and Ambiguus Nuclei</i>  | 306 | <b>Cranial Motor Nuclei</b>                                      | 313 |
| <i>Ventral, Medial, and Dorsal Reticular Nuclei</i>   | 306 | <i>Hypoglossal Nucleus</i>                                       | 313 |
| <i>Mesencephalic Reticular Formation</i>  | 306 | <i>Facial Nucleus</i>  | 313 |
| <i>Lateral Reticular Nucleus</i>  | 307 | <i>Motor Trigeminal Nucleus</i>                                  | 313 |
| <i>Gigantocellular, Lateral Paragigantocellular, Gigantocellular Ventral Part, Gigantocellular Alpha Part, and Dorsal Paragigantocellular, and Parvicellular Reticular Nuclei</i> | 307 | <i>Abducens Nucleus</i>  | 313 |
| <b>Tegmental Nuclei</b>   | 308 | <i>Trochlear Nucleus</i>   | 313 |
| <i>Ventral Tegmental Nucleus</i>  | 308 | <i>Oculomotor Nucleus</i>  | 313 |
| <i>Dorsal Tegmental Nucleus</i>   | 308 | <b>Somatosensory System</b>                                      | 314 |
| <i>Posterodorsal Tegmental Nucleus</i>  | 309 | <i>Gracile Nucleus</i>   | 314 |
| <i>Laterodorsal Tegmental Nucleus</i>   | 309 | <i>Cuneate Nucleus</i>   | 314 |
| <i>Pedunculotegmental Nucleus</i>   | 309 | <i>External Cuneate Nucleus</i>                                  | 314 |
| <i>Microcellular Tegmental Nucleus</i>  | 309 | <i>Pericuneate, Peritrigeminal, X, and Paratrigeminal Nuclei</i> | 314 |
|   |     | <i>Medial Pericuneate Nucleus</i>                                | 314 |

|  |            |   |            |
|--|------------|---|------------|
| Lateral Pericuneate Nucleus  | 314        | <i>Superior Colliculus</i>                                      | 318        |
| Peritrigeminal Nucleus   | 314        | <i>Parabigeminal Nucleus</i>                                    | 318        |
| Afferent Connections of the Pericuneate<br>and Peritrigeminal Nuclei | 315        | <i>Medial Terminal Nucleus of the Accessory Optic<br/>Tract</i> | 318        |
| Nucleus X  | 315        | <b>Precerebellar Nuclei and Red Nucleus</b>                     | <b>318</b> |
| Paratrigeminal Nucleus   | 315        | <i>Inferior Olive</i>   | 319        |
| <i>Spinal Trigeminal Nucleus</i>                                     | 316        | <i>Medial Accessory Olive</i>                                   | 319        |
| <i>Mesencephalic Trigeminal Nucleus</i>                              | 316        | <i>Beta Nucleus</i>   | 319        |
| <i>Endolemniscal Nucleus</i>   | 316        | <i>Dorsomedial Cell Column</i>                                  | 319        |
| <i>B9 and Supralemniscal Nucleus</i>                                 | 316        | <i>Ventrolateral Outgrowth</i>                                  | 319        |
| <b>Vestibular Nuclei</b>   | <b>316</b> | <i>Cap of Kooy</i>  | 319        |
| <i>Medial Vestibular Nucleus</i>                                     | 316        | <i>Dorsal Accessory Olive</i>                                   | 319        |
| <i>Spinal Vestibular Nucleus</i>                                     | 316        | <i>Principal Inferior Olive</i>                                 | 319        |
| <i>Lateral Vestibular Nucleus</i>                                    | 317        | <i>Conterminal Nucleus</i>                                      | 319        |
| <i>Interstitial Nucleus of the Eighth Nerve</i>                      | 317        | <i>Arcuate Nucleus</i>  | 319        |
| <i>Nucleus of Origin of Vestibular Efferents</i>                     | 317        | <i>Paramedian and Dorsal Paramedian Nuclei</i>                  | 320        |
| <b>Auditory System</b>   | <b>317</b> | <i>Intercalated Nucleus</i>                                     | 320        |
| <i>Ventral and Dorsal Cochlear Nuclei</i>                            | 317        | <i>Prepositus and Interpositus Nuclei</i>                       | 320        |
| <i>Superior Olive</i>  | 317        | <i>Cribriform Nucleus</i>                                       | 320        |
| <i>Trapezoid Nucleus</i>   | 317        | <i>Pontine Nuclei</i>   | 320        |
| <i>Nuclei of the Lateral Lemniscus</i>                               | 318        | <i>Red Nucleus</i>  | 321        |
| <i>Inferior Colliculus</i>   | 318        | <i>Cerebral Peduncle</i>  | 321        |
| <i>Nucleus of the Brachium of the Inferior Colliculus</i>            | 318        | <b>Conclusion</b>   | <b>321</b> |
| <i>Medial Geniculate</i>   | 318        | <i>Acknowledgment</i>   | 321        |
| <b>Visual System</b>   | <b>318</b> |   |            |

This chapter describes human homologs of nuclei identified in the brainstem of other mammals and attempts to extend to the human the overall organizational schemata that have been proposed for the brainstem of other mammalian species. We present herein updated diagrams of the *Atlas of the Human Brainstem* (Paxinos and Huang, 1995). The diagrams have been thoroughly revised in light of our recent work on the rat (Paxinos and Watson, 2007) and rhesus monkey (Paxinos et al., 3<sup>rd</sup> ed, in *BrainNavigator*, Elsevier, 2010) as well as our work on the marmoset (*Atlas of the Marmoset Brain in Stereotaxic Coordinates*, Paxinos et al., (2012)).

Structures of the brainstem are very diverse with respect to functions they participate in, neuroactive elements they contain, and neural pathways they accommodate. As a reflection, the anatomical organization of the human brainstem is a complex amalgam of compact neuronal groups and dispersed cell areas with varying cytoarchitecture. Many of these neurons, nuclei, and areas are given elaborate descriptions in separate chapters of this book that deal with associated functional networks, whereas the purpose of this chapter is to present an account of human brainstem

nuclei and areas with discrete emphasis on the structural organization of the region, rather than functional, chemical, or pathological characteristics. It would have been inappropriate, however, to discount apparent functional characteristics of some brainstem structures, particularly when such characteristics can be used to systematize the diversity of brainstem neuronal groups. This chapter discusses a number of human brainstem structures in relation to autonomic function, vestibular system, visual system, auditory system, motor cranial nerves, or somatosensory system. However, many brainstem structures are not obviously related to a particular function, or are related to a number of functions or better known for their structural characteristics. Thus, the reticular formation, precerebellar nuclei, red nucleus, locus coeruleus, and raphe nuclei are distinguished as complex structural entities and discussed in approximate rostrocaudal order. This chapter also describes the distribution of some neuroactive chemicals to rationalize the details of structural delineations. There has been considerable attention on the chemoarchitecture of the brainstem in other species, most commonly in rodents. This chapter, however, focuses on examination of human brainstem chemoarchitecture.

Following the original suggestion of Paxinos and Huang (1995), we also acknowledge that the radial arrangement of the human caudal hindbrain with reference to the fourth ventricle (as King, 1980, proposed for the cat) is more tenable than the “quilt” pattern proposed by Olszewski and Baxter (1954). Thus, it appears that the human caudal hindbrain is organized roughly in columns, commencing with a special afferent zone (vestibular nuclei) dorsolaterally and terminating in a general motor efferent zone ventromedially (hypoglossal). Intervening in a dorsal-to-ventral sequence are the somatic afferent column (spinal nucleus of the trigeminal), the visceral afferent column (solitary nucleus and the dorsolateral slab of the intermediate reticular zone), and the visceral or branchial efferent column (dorsal motor nucleus of vagus, ambiguus, and the ventromedial part of IRt). A scheme of organization along these lines was suggested by Herrick (1922) for the cranial nerve nuclei and is now popularly used in many neuroanatomy textbooks.

Traditionally, nuclei have been identified using cytoarchitecture, myeloarchitecture, and connectivity. In the last 20 years, researchers have used developmental, functional, and, increasingly, chemoarchitectonic criteria to complement these traditional methods (Heimer and Wilson, 1975; Krettek and Price, 1978; Paxinos and Watson, 1998; Koutcherov et al., 2000). We are of the view that for the establishment of homologies it is necessary that the human and rat brainstem be studied in parallel using the same criteria. The criteria used for establishing homologies in the present study are morphological and include cytoarchitecture, chemoarchitecture, topography, and subnuclear organization.

Work based on chemoarchitectonic analysis began after Koelle and Friedenwald (1949) developed a simple histochemical method for revealing acetylcholinesterase (AChE), the degradative enzyme for acetylcholine. The application of AChE staining has subsequently been proven very useful in distinguishing brain areas. A comprehensive delineation of the rat brain by Paxinos and Watson (1982) was done largely on the basis of AChE reactivity with Nissl staining used as a secondary criterion. In the last 30 years, AChE histochemistry has been successfully used for delineation of the brain in many mammalian species. Most importantly, AChE histochemistry works well on the fresh (unfixed) post-mortem human brain, which allows this method to be successfully applied to the neuroanatomical delineation of the human brain. For example, AChE staining was used in pathological studies of the brains of patients with Alzheimer’s disease (Saper and German, 1987) and was employed to reveal the organization of the human hypothalamus (Koutcherov et al., 2000). Because the AChE content of homologous nuclei is reasonably

stable across mammalian species, this chapter relies mainly on AChE distribution to illustrate brainstem homologies. We have also considered cell morphology and the distribution of tyrosine hydroxylase (Chapter 13), phenylalanine hydroxylase (Chapter 11), substance P (Halliday et al., 1988a), and neuropeptide Y (Halliday et al., 1988c). Some connectivity data were available to us from therapeutic cordotomies (Mehler, 1974a). All findings reported here concern the human unless otherwise stated.

Figures 8.1–8.64 are updates of the diagrams found in *Atlas of the Human Brainstem* (Paxinos, G., and Huang, X.F., 1995, Academic Press, San Diego). The reader can find the photographic plates on which the current diagrams are based in the Paxinos and Huang (1995) atlas.

The coronal maps of the human brainstem are presented in sections at 2-mm intervals. The medullary tissue depicted in Figures 8.1–8.64 was obtained by Paxinos and Huang (1995) 4 h post mortem from a 59-year-old white male who died suddenly from a heart attack. The donor had no medical history of any neurological or psychiatric disease.

Naked Arabic numerals have been used to denote cortical areas, cortical layers, cranial nerve nuclei and spinal cord layers. Having to contend with the cortical areas in primates, we decided to use A before the Arabic numerals denoting cortical areas. This meant that we could no longer use A1, A8, A11, A13, or A14 for the catecholamine cell groups. The Swedes did not know what was noradrenaline (norepinephrine), what adrenaline (epinephrine) and what dopamine when they discovered these cell groups. Now, however, we know and we have specified them by changing to A1 to NA1, C1 to Ad1, A5 to NA5, A7 to NA7, A8 to DA8, etc.

## ABBREVIATIONS USED IN THE FIGURES

---

|      |  |
|------|--|
| 3N   | oculomotor nucleus                                   |
| 3n   | oculomotor nerve                                     |
| 4N   | trochlear nucleus                                    |
| 4n   | trochlear nerve                                      |
| 4V   | 4th ventricle  |
| 5ADi | motor trigeminal nucleus, anterior digastric part    |
| 5Ma  | motor trigeminal nucleus, masseter part              |
| 5MHy | mylohyoid subnucleus of the motor trigeminal nucleus |
| 5N   | motor trigeminal nucleus                             |
| 5PC  | motor trigeminal nucleus, parvicellular part         |
| 5Sol | trigeminal-solitary transition zone                  |

|       |   |       |  |
|-------|---|-------|--|
| 5Sp   | lamina 5 of the spinal gray                             | Ad1   | C1 adrenaline cells                                |
| 5Pt   | motor trigeminal nucleus, pterygoid part                | Ad2   | C2 adrenaline cells                                |
| 5Te   | motor trigeminal nucleus, temporalis part               | AHi,  | amygdalohippocampal area                           |
| 5Tr   | trigeminal transition zone                              | AmbC  | ambiguus nucleus, compact part                     |
| 6N    | abducens nucleus  | AmbL  | ambiguus nucleus, loose part                       |
| 6n    | abducens nerve  | AmbSC | ambiguus nucleus, semicompact part                 |
| 7DI   | facial nucleus, dorsal intermediate subnucleus          | Amg   | amygdaloid nucleus                                 |
| 7DM   | facial nucleus, dorsomedial subnucleus                  | ami   | amiculum of the olive                              |
| 7I    | facial nucleus, intermediate part                       | AP    | area postrema                                      |
| 7L    | facial nucleus, lateral subnucleus                      | APT   | anterior pretectal nucleus                         |
| 7N    | facial nucleus  | Aq    | aqueduct   |
| 7n    | facial nerve  | Ar    | arcuate nucleus of the caudal hindbrain            |
| 7SH   | facial motor nucleus, stylohyoid part                   | asc7  | ascending fibers of the facial nerve               |
| 7Sp   | lamina 7 of the spinal gray                             | asp   | anterior spinal artery                             |
| 7VI   | facial nucleus, ventral intermediate subnucleus         | Au    | austral nucleus                                    |
| 7VL   | facial nucleus, ventrolateral subnucleus                | AVC   | anteroventral cochlear nucleus                     |
| 7VM   | facial nucleus, ventromedial subnucleus                 | Bar   | Barrington's nucleus                               |
| 8Sp   | lamina 8 of the spinal gray                             | B9    | B9 serotonin cells                                 |
| 8n    | vestibulocochlear nerve                                 | BL    | basolateral amygdaloid nucleus                     |
| 8vn,  | vestibular root of the vestibulocochlear nerve          | basv  | basal vein (drains into cavernous sinus)           |
| 9n    | glossopharyngeal nerve                                  | bic   | brachium of the inferior colliculus                |
| 9Sp   | lamina 9 of the spinal gray                             | BIC   | nucleus of the brachium of the inferior colliculus |
| 10N   | vagus nerve nucleus                                     | BL    | basolateral amygdaloid nucleus                     |
| 10Ca  | dorsal motor nucleus of vagus, caudal part              | Bo    | Botzinger complex                                  |
| 10CaI | dorsal motor nucleus of vagus, caudointermediate part   | bsc   | brachium of the superior colliculus                |
| 10CeI | dorsal motor nucleus of vagus, centroiintermediate part | CA1   | field CA1 of the hippocampus                       |
| 10DI  | dorsal motor nucleus of vagus, dorsointermediate part   | CA3   | field CA3 of the hippocampus                       |
| 10DR  | dorsal motor nucleus of vagus, dorsorostral part        | CAT   | central nucleus of the acoustic tract              |
| 10F   | dorsal motor nucleus of vagus, medial fringe            | Cb    | cerebellum   |
| 10n   | vagus nerve   | cbu   | corticobulbar tract                                |
| 10RI, | dorsal motor nucleus of vagus, rostrointermediate part  | CC    | central canal                                      |
| 10Sp  | lamina 10 of the spinal gray                            | CDPMn | caudal dorsal paramedian nucleus                   |
| 10Tr  | vagal trigone   | CeCv  | central cervical nucleus of the spinal cord        |
| 10VI  | dorsal motor nucleus of vagus, ventroiintermediate part | CeMe  | central mesencephalic nucleus                      |
| 10VR  | dorsal motor nucleus of vagus, ventrorostral part       | CGPn  | central gray of the rhombencephalon                |
| 11n   | vagus nerve   | chp   | chorioid plexus                                    |
| 11N   | accessory nerve nucleus                                 | CIC   | central nucleus of the inferior colliculus         |
| 12N   | hypoglossal nucleus                                     | CIF   | compact interfascicular nucleus                    |
| 12GH  | hypoglossal nucleus, geniohyoid part                    | CLiAz | caudal linear nucleus of the raphe, azygoz part    |
| 12L   | hypoglossal nucleus, lateral part                       | CLiZ  | caudal linear nucleus of the raphe, zygoz part     |
| 12M   | hypoglossal nucleus, medial part                        | CnF   | cuneiform nucleus                                  |
| 12n   | hypoglossal nerve                                       | cp    | cerebral peduncle                                  |
| 12V   | hypoglossal nucleus, ventral part                       | esp   | corticospinal tract                                |
| 12VL  | hypoglossal nucleus, ventrolateral part                 | Crb   | cribiform nucleus                                  |

|       |   |       |   |
|-------|---|-------|---|
| csc   | commissure of the superior colliculus       | EVe   | nucleus of origin of vestibular efferents of the vestibular nerve       |
| Ct    | conterminal nucleus                         | EW    | Edinger-Westphal nucleus  |
| ctg   | central tegmental tract                     | fr    | fasciculus retroflexus  |
| cu    | cuneate fasciculus                          | fpn   | frontopontine fibers  |
| Cu    | cuneate nucleus                             | FVe   | F-cell group of the vestibular complex                                  |
| CuR   | cuneate nucleus, rotundus part              | Gam   | gamma pontine nucleus   |
| CuT   | cuneate nucleus, triangular part            | g7    | genu of the facial nerve  |
| Cx    | cerebral cortex                             | Gi    | gigantocellular reticular nucleus                                       |
| das   | dorsal acoustic stria                       | GiV   | gigantocellular reticular nucleus, ventral part                         |
| DA8   | dopamine cells A8                           | GiA   | gigantocellular reticular nucleus, alpha part                           |
| DC    | dorsal cochlear nucleus                     | Gr    | gracile nucleus   |
| DCIC  | dorsal cortex of the inferior colliculus    | gr    | gracile fasciculus  |
| DG    | dentate gyrus                               | GrC   | granular cell layer of cochlear nuclei                                  |
| Dk    | nucleus of Darkschewitsch                   | hio   | hilus of the inferior olive   |
| dlf   | dorsal longitudinal fasciculus              | I3    | interoculomotor nucleus   |
| DLG   | dorsal lateral geniculate nucleus           | I5    | intertrigeminal nucleus   |
| DLL   | dorsal nucleus of the lateral lemniscus     | I8    | interstitial nucleus of the vestibulocochlear nerve                     |
| DLPAG | dorsolateral periaqueductal gray            | ia    | internal arcuate fibers   |
| DMPAG | dorsomedial periaqueductal gray             | icp   | inferior cerebellar peduncle (restiform body)                           |
| DM5   | dorsomedial spinal trigeminal nucleus       | icv   | inferior cerebellar vein  |
| DMSp5 | dorsomedial spinal trigeminal nucleus       | IF    | interfascicular nucleus   |
| dms   | dorsomedian sulcus                          | IFH   | interfascicular hypoglossal nucleus                                     |
| dpms  | dorsal paramedian sulcus                    | II    | intermediate interstitial nucleus of the medial longitudinal fasciculus |
| DMTg  | dorsomedial tegmental area                  | ILL   | intermediate nucleus of the lateral lemniscus                           |
| DpG   | deep gray layer of the superior colliculus  | IMLF  | interstitial nucleus of the medial longitudinal fasciculus              |
| DPGi  | dorsal paragigantocellular nucleus          | In    | intercalated nucleus  |
| DPO   | dorsal periolivary nucleus                  | InC   | interstitial nucleus of Cajal   |
| DpWh  | deep white layer of the superior colliculus | InCSh | interstitial nucleus of Cajal, shell                                    |
| DR    | dorsal raphe nucleus                        | InG   | intermediate gray layer of the superior colliculus                      |
| DRC   | dorsal raphe nucleus, caudal part           | InWh  | intermediate white layer of the superior colliculus                     |
| DRD   | dorsal raphe nucleus, dorsal part           | IO    | inferior olive  |
| DRI   | dorsal raphe nucleus, interfascicular part  | IOA   | inferior olive, subnucleus A of medial nucleus                          |
| DRL   | dorsal raphe nucleus, lateral part          | IOB   | inferior olive, subnucleus B of medial nucleus                          |
| DRV   | dorsal raphe nucleus, ventral part          | IoBe  | inferior olive, beta subnucleus   |
| dsc   | dorsal spinocerebellar tract                | IOC   | inferior olive, subnucleus C of medial nucleus                          |
| dtg   | dorsal tegmental bundle                     | IOD   | inferior olive, dorsal nucleus  |
| DTgC  | dorsal tegmental nucleus, central part      | IODC  | inferior olive, dorsal nucleus, caudal part                             |
| DTgP  | dorsal tegmental nucleus, pericentral part  | IODM  | inferior olive, dorsomedial cell group                                  |
| E     | ependyma and subependymal layer             | IOK   | inferior olive, cap of Kooy of the medial nucleus                       |
| EC    | epicoeruleus nucleus                        | IOM   | inferior olive, medial nucleus  |
| ECIC  | external cortex of the inferior colliculus  | IOPr  | inferior olive, principal nucleus                                       |
| ECu   | external cuneate nucleus                    | IOVL  | inferior olive, ventrolateral protrusion                                |
| EF    | epifascicular nucleus                       | IP    | interpeduncular nucleus   |
| EL    | endolemniscal nucleus                       |       |   |



|       |  |         |   |
|-------|--|---------|---|
| IPA   | interpeduncular nucleus, apical subnucleus                         | m5      | motor root of the trigeminal nerve                |
| IPC   | interpeduncular nucleus, caudal subnucleus                         | MA3     | medial accessory oculomotor nucleus               |
| IPDM  | interpeduncular nucleus, dorsomedial subnucleus                    | MB      | mammillary body                                   |
| IPF   | interpeduncular fossa  | MdD     | medullary reticular nucleus, dorsal part          |
| IPI   | interpeduncular nucleus, intermediate subnucleus                   | mdosa   | median dorsal spinal artery (branch of radicular) |
| IPL   | interpeduncular nucleus, lateral subnucleus                        | MdV     | medullary reticular nucleus, ventral part         |
| IPo   | interpositus   | mcp     | middle cerebellar peduncle                        |
| IPR   | interpeduncular nucleus, rostral subnucleus                        | MCPC    | magnocellular nucleus of the posterior commissure |
| ipt   | interpedunculotegmental tract                                      | Me5     | mesencephalic trigeminal nucleus                  |
| IRt   | intermediate reticular nucleus                                     | me5     | mesencephalic trigeminal tract                    |
| IS    | inferior salivatory nucleus  | MeF     | dorsal motor nucleus of vagus, medial fringe      |
| isRt  | isthmus reticular formation  | MG      | medial geniculate nucleus                         |
| jx    | juxtarestiform body  | MGD     | medial geniculate nucleus, dorsal part            |
| JxO   | juxtaolivary nucleus   | MGM     | medial geniculate nucleus, medial part            |
| KF    | Kölliker–Fuse nucleus  | MGV     | medial geniculate nucleus, ventral part           |
| LC    | locus coeruleus  | MiTg    | microcellular tegmental nucleus                   |
| lcs   | lateral corticospinal tract  | ml      | medial lemniscus                                  |
| LDTg  | laterodorsal tegmental nucleus                                     | ML      | medial mammillary nucleus, lateral part           |
| LDTgV | laterodorsal tegmental nucleus, ventral part                       | mlf     | medial longitudinal fasciculus                    |
| lf    | lateral funiculus  | MnR     | median raphe nucleus                              |
| lfp   | longitudinal fibers of the pons                                    | Mo5     | motor trigeminal nucleus                          |
| Li    | linear nucleus of the hindbrain                                    | mp      | mammillary peduncle                               |
| ll    | lateral lemniscus  | MPB     | medial parabrachial nucleus                       |
| LPAG  | lateral periaqueductal gray  | MPBE    | medial parabrachial nucleus, external part        |
| LPB   | lateral parabrachial nucleus                                       | MPCu    | medial pericuneate nucleus                        |
| LPBC  | lateral parabrachial nucleus, central part                         | mRt     | mesencephalic reticular formation                 |
| LPBD  | lateral parabrachial nucleus, dorsal part                          | mscb    | middle superior cerebellar artery                 |
| LPBE  | lateral parabrachial nucleus, external part                        | MSO     | medial superior olive                             |
| LPBS  | lateral parabrachial nucleus, superior part                        | mtg     | mammillotegmental tract                           |
| LPCu  | lateral pericuneate nucleus  | MVe     | medial vestibular nucleus                         |
| LPGi  | lateral paragigantocellular nucleus                                | MVeMC   | medial vestibular nucleus, magnocellular part     |
| LR4V  | lateral recess of the 4th ventricle                                | MVePC   | medial vestibular nucleus, parvocellular part     |
| LRt   | lateral reticular nucleus  | MVPO    | medioventral periolivary nucleus                  |
| LRtPC | lateral reticular nucleus, parvocellular part                      | Mx      | matrix region of the rhombencephalon              |
| LRtS5 | lateral reticular nucleus, subtrigeminal part                      | MZMG    | marginal zone of the medial geniculate nucleus    |
| lscb  | lateral superior cerebellar artery (branch of superior cerebellar) | NA1     | noradrenaline cells A1                            |
| LSO   | lateral superior olive   | NA1/Ad1 | noradrenaline cells A1 and/or adrenaline cells C1 |
| LT    | lateral terminal nucleus of the accessory optic tract              | NA2     | noradrenaline cells A2                            |
| Lth   | lithoid nucleus  | NA2/Ad2 | noradrenaline cells and/or adrenaline cells C2    |
| LV    | lateral ventricle  | NA5     | noradrenaline cells A5                            |
| LVe   | lateral vestibular nucleus   | NA7     | noradrenaline cells A7                            |
| LVPO  | lateroventral periolivary nucleus                                  | Nt      | noto cuneate nucleus                              |
| lvs   | lateral vestibulospinal tract                                      | oc      | olivocerebellar tract                             |
|       |  | ocb     | olivocochlear bundle                              |



|       |  |       |  |
|-------|--|-------|--|
| ocpn  | occipitopontine fibers                                       | pos   | preolivary sulcus  |
| ODPMn | oral dorsal paramedian nucleus                               | PoT   | posterior thalamic nuclear group, triangular part            |
| Op    | optic nerve layer of the superior colliculus                 | PP    | peripeduncular nucleus                                       |
| opt   | optic tract  | PTg   | pedunculotegmental nucleus                                   |
| p1PAG | p1 periaqueductal gray                                       | Pr    | prepositus nucleus   |
| p1Rt  | p1 reticular formation                                       | Pr5   | principal sensory trigeminal nucleus                         |
| Pa4   | paratrochlear nucleus  | PrEW  | pre-Edinger-Westphal nucleus                                 |
| P5    | peritrigeminal zone  | PrBo  | pre-Botzinger complex  |
| P7    | perifacial zone  | PrC   | precommissural nucleus                                       |
| Pa5   | paratrigeminal nucleus                                       | PrCnF | precuneiform area  |
| Pa6   | paraabducens nucleus   | PSol  | parasolitary nucleus   |
| PaP   | parapeduncular nucleus                                       | psp   | posterior spinal artery                                      |
| PaRa  | pararaphales nucleus   | ptpn  | parietal pontine fibers                                      |
| PaS   | parasubiculum  | Pul   | pulvinar nuclei  |
| PaVe  | paravestibular nucleus                                       | PVM   | posterior ventromedial thalamic nucleus                      |
| PBG   | prabigeminal nucleus   | py    | pyramidal tract  |
| PBP   | parabrachial pigmented nucleus of the ventral tegmental area | pyx   | pyramidal decussation  |
| pc    | posterior commissure   | RAmb  | retroambiguus nucleus  |
| PC3   | parvicellular oculomotor nucleus                             | Rbd   | rhabdoid nucleus   |
| PCom  | nucleus of the posterior commissure                          | RC    | raphe cap  |
| PCRt  | parvicellular reticular nucleus                              | RIP   | raphe interpositus nucleus                                   |
| PCRtA | parvicellular reticular nucleus, alpha part                  | RIs   | retroisthmic nucleus   |
| PCuMx | pericuneate matrix   | RLi   | rostral linear nucleus                                       |
| PDR   | posterodorsal raphe nucleus                                  | RM    | retromamillary nucleus                                       |
| PDTg  | posterodorsal tegmental nucleus                              | RMC   | red nucleus, magnocellular part                              |
| PIF   | parainterfascicular nucleus                                  | RMg   | raphe magnus nucleus   |
| Pe5   | peritrigeminal nucleus                                       | Ro    | nucleus of Roller  |
| PF    | parafascicular thalamic nucleus                              | ROb   | raphe obscurus nucleus                                       |
| pica  | posterior inferior cerebellar artery                         | RPa   | raphe pallidus nucleus                                       |
| PIL   | posterior intralaminar thalamic nucleus                      | RPC   | red nucleus, parvicellular part                              |
| PIGL  | pleioglial periaqueductal gray                               | RPF   | retroparafascicular nucleus                                  |
| PLi   | limitans thalamic nucleus, posterior part                    | RPn   | raphe pontis nucleus   |
| pm    | principal mammillary tract                                   | RRF   | retrobulbar field  |
| PMnR  | paramedian raphe nucleus                                     | rs    | rubrospinal tract  |
| PN    | paranigral nucleus of ventral tegmental area                 | RtTg  | reticulotegmental nucleus                                    |
| Pn    | pontine nuclei   | RtTgL | reticulotegmental nucleus, lateral part                      |
| PnB   | pontobulbar nucleus  | RTz   | retrotrapezoid nucleus                                       |
| PnC   | pontine reticular nucleus, caudal part                       | RVL   | rostroventrolateral reticular nucleus of the rhombencephalon |
| PnO   | pontine reticular nucleus, oral part                         | RVRG  | rostral ventral respiratory group                            |
| Po    | posterior thalamic nuclear group                             | S     | subiculum  |
| PoDG  | polymorph layer of the dentate gyrus                         | s5    | sensory root of the trigeminal nerve                         |
| pof   | post-olivary fissure   | Sag   | sagulum nucleus  |
| pola  | paraolivary artery   | SC    | superior colliculus  |
| polv  | paraolivary vein   | scol  | supracollicular arterial network                             |

|         |  |       |  |
|---------|--|-------|--|
| scp     | superior cerebellar peduncle                       | SubCD | subcoeruleus nucleus, dorsal part                      |
| scpd    | superior cerebellar peduncle, descending limb      | SubCV | subcoeruleus nucleus, ventral part                     |
| SG      | supragenulate thalamic nucleus                     | SuG   | superficial gray layer of the superior colliculus      |
| SGe     | supragenual nucleus                                | SuL   | supralemniscal nucleus                                 |
| sl      | sulcus limitans                                    | SuM   | supramammillary nucleus                                |
| smv     | superior medullary velum                           | SuVe  | superior vestibular nucleus                            |
| SNC     | substantia nigra, compact part                     | tepn  | temporopontine fibers                                  |
| SNCD    | substantia nigra, compact part, dorsal tier        | tfp   | transverse fibers of the pons                          |
| SNCM    | substantia nigra, compact part, medial tier        | ts    | tectospinal tract                                      |
| SNCV    | substantia nigra, compact part, ventral tier       | tth   | trigeminothalamic tract (trigeminal lemniscus)         |
| SND     | substantia nigra, dorsal part                      | Tz    | nucleus of the trapezoid body                          |
| SNL     | substantia nigra, lateral part                     | tz    | trapezoid body   |
| SNR     | substantia nigra, reticular part                   | U     | nucleus U  |
| SNV     | substantia nigra, ventral part                     | vcs   | ventral corticospinal tract                            |
| Sol     | solitary nucleus                                   | VCP   | ventral cochlear nucleus, posterior part               |
| sol     | solitary tract                                     | veme  | vestibulomesencephalic tract                           |
| SolC    | solitary nucleus, commissural part                 | vf    | ventral funiculus                                      |
| SolD    | solitary nucleus, dorsal part                      | VH    | ventral horn   |
| SolDL   | solitary nucleus, dorsolateral part                | VLL   | ventral nucleus of the lateral lemniscus               |
| SolG    | solitary nucleus, gelatinous part                  | vlmv  | ventrolateral medullary vein                           |
| SolI    | solitary nucleus, interstitial part                | vl    | ventrolateral sulcus                                   |
| SolIM   | solitary nucleus, intermediate part                | VLPAG | ventrolateral periaqueductal gray                      |
| SolM    | solitary nucleus, medial part                      | VLTg  | ventrolateral tegmental area                           |
| SolPaC  | solitary nucleus, paracommissural part             | vmf   | ventral median fissure                                 |
| SolV    | solitary nucleus, ventral part                     | VPI   | ventral posterior inferior nucleus                     |
| SolVL   | solitary nucleus, ventrolateral part               | VPM   | ventral posteromedial thalamic nucleus                 |
| Sp5     | spinal trigeminal nucleus                          | vcs   | ventral corticospinal tract                            |
| sp5     | spinal trigeminal tract                            | vr    | ventral root   |
| Sp5C    | spinal trigeminal nucleus, caudal part             | vsc   | ventral spinocerebellar tract                          |
| Sp5C1   | spinal trigeminal nucleus, caudal part, lamina 1   | vspa  | ventral spinal artery (branch of vertebral, radicular) |
| Sp5C2   | spinal trigeminal nucleus, caudal part, lamina 2   | VTA   | ventral tegmental area                                 |
| Sp5C3/4 | spinal trigeminal nucleus, caudal part, lamina 3/4 | VTAR  | ventral tegmental area, rostral part                   |
| Sp5I    | spinal trigeminal nucleus, interpolar part         | vtg   | ventral tegmental tract                                |
| Sp5O    | spinal trigeminal nucleus, oral part               | VTg   | ventral tegmental nucleus (Gudden)                     |
| SPO     | superior paraolivary nucleus                       | vtgx  | ventral tegmental decussation                          |
| SPP     | subpeduncular pigmented nucleus                    | X     | nucleus X  |
| spth    | spinothalamic tract                                | x4 n  | decussation of the trochlear nerve                     |
| SpVe    | spinal vestibular nucleus                          | xml   | decussation of the medial lemniscus                    |
| STh     | subthalamic nucleus                                | xscp  | decussation of the superior cerebellar peduncle        |
| Su3     | supraoculomotor periaqueductal gray                | Y     | nucleus Y  |
| Su3C    | supraoculomotor cap                                | Z     | nucleus Z  |
| Su5     | supratrigeminal nucleus                            | ZI    | zona incerta   |
| SubB    | subbrachial nucleus                                | Zo    | zonal layer of the superior colliculus                 |
| SubC    | subcoeruleus nucleus                               |       |  |

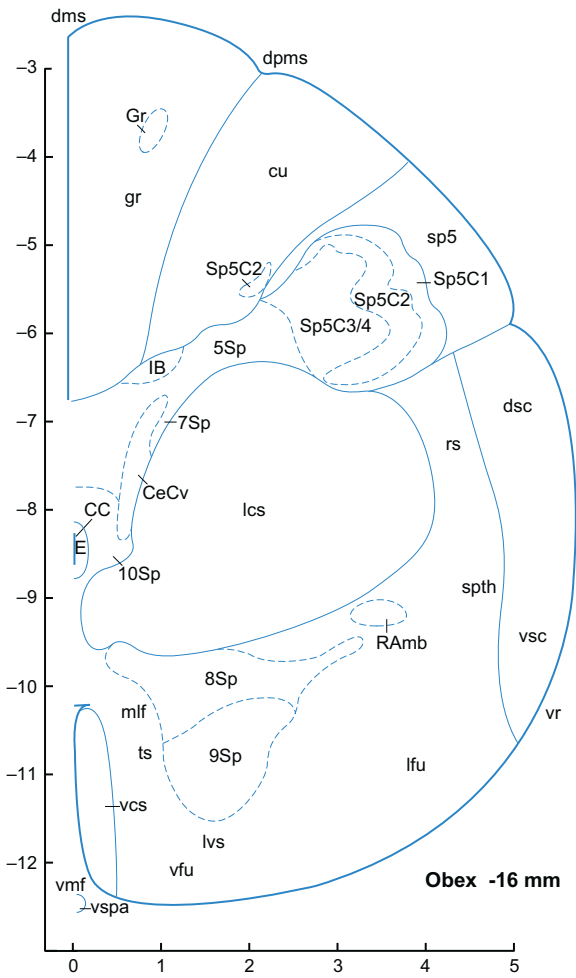


FIGURE 8.1 ■

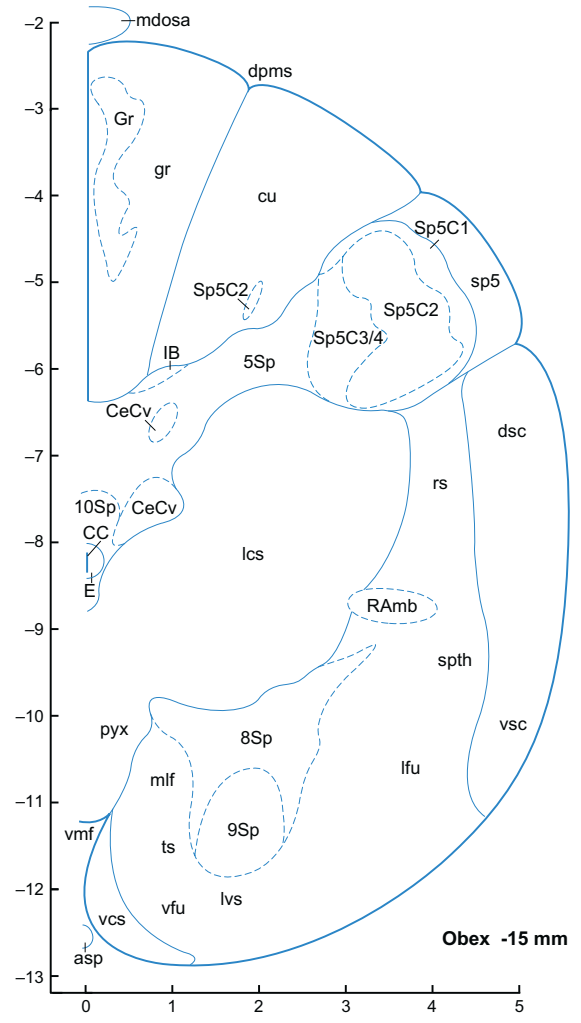


FIGURE 8.2 ■

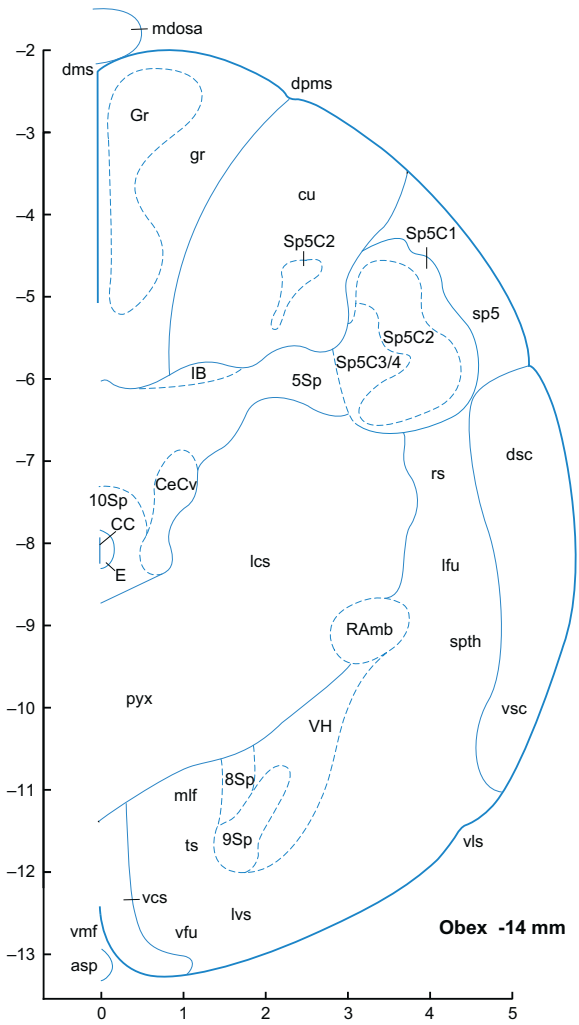


FIGURE 8.3 ■

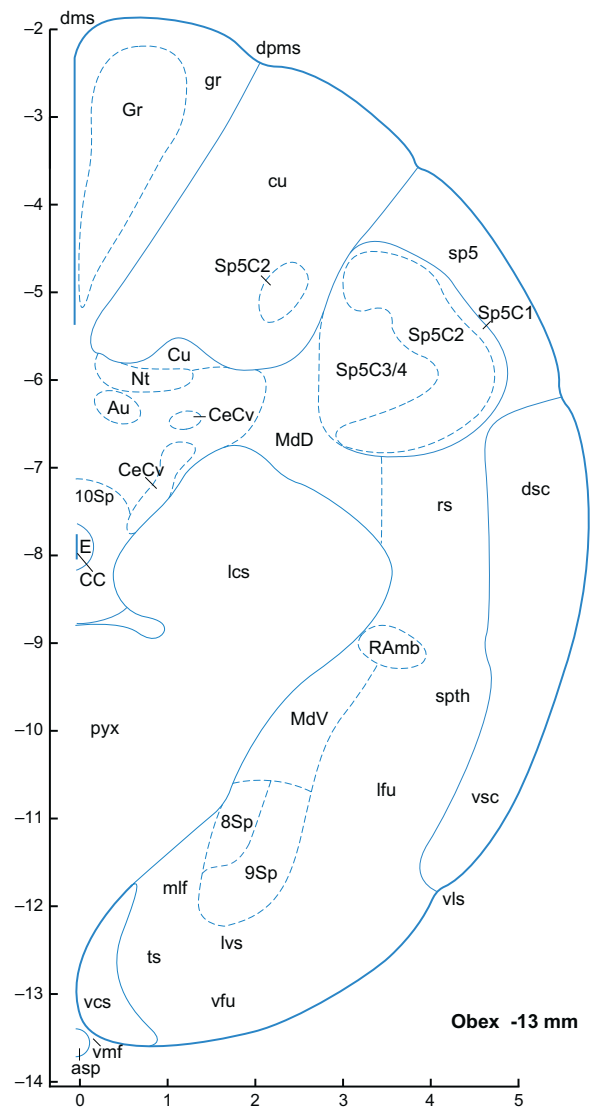


FIGURE 8.4 ■

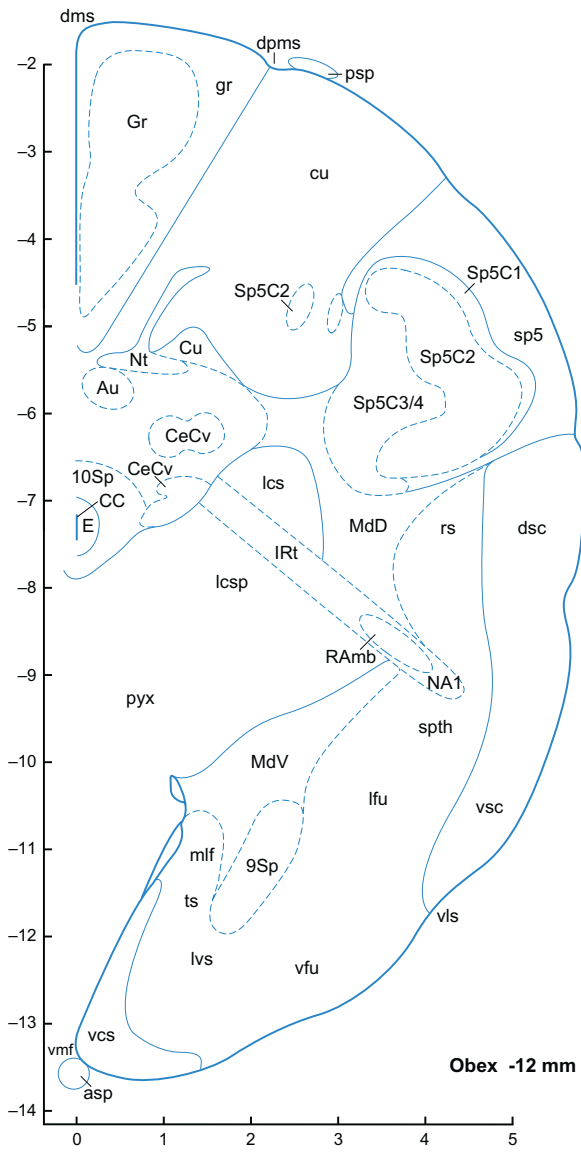


FIGURE 8-5 ■

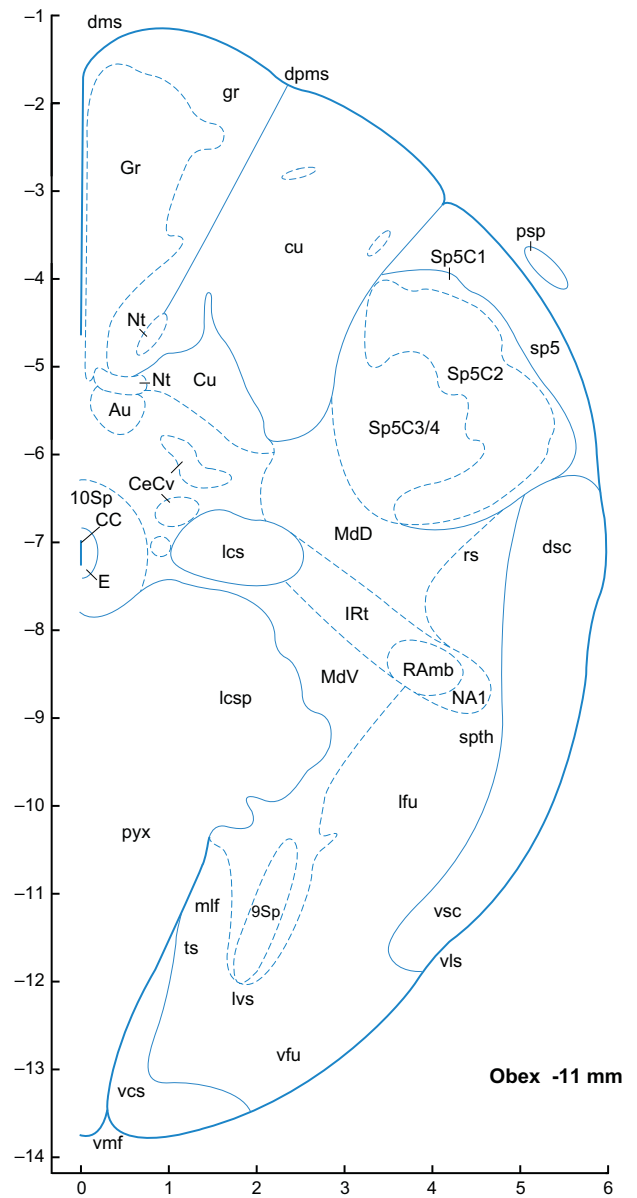


FIGURE 8-6 ■

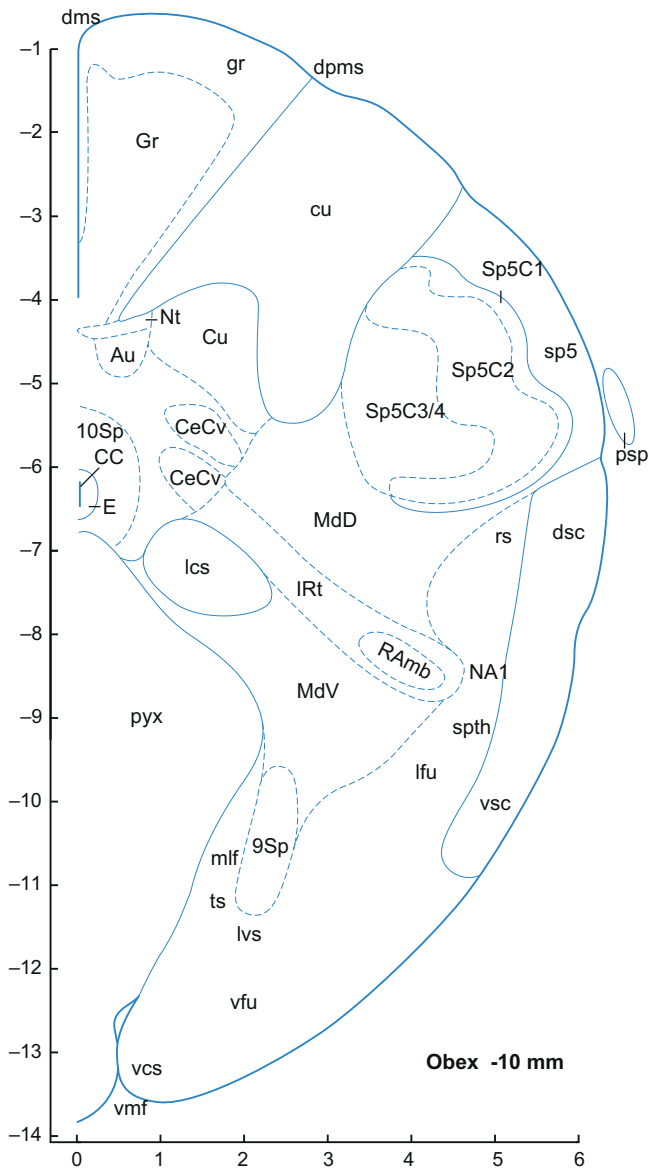


FIGURE 8.7 ■

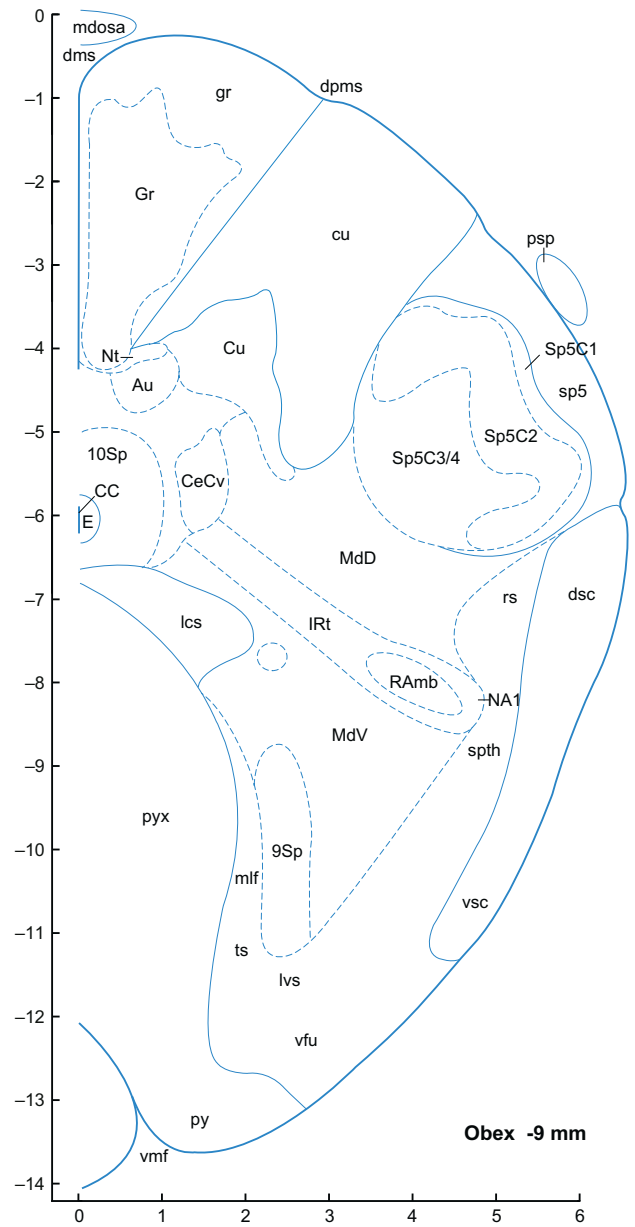


FIGURE 8.8 ■

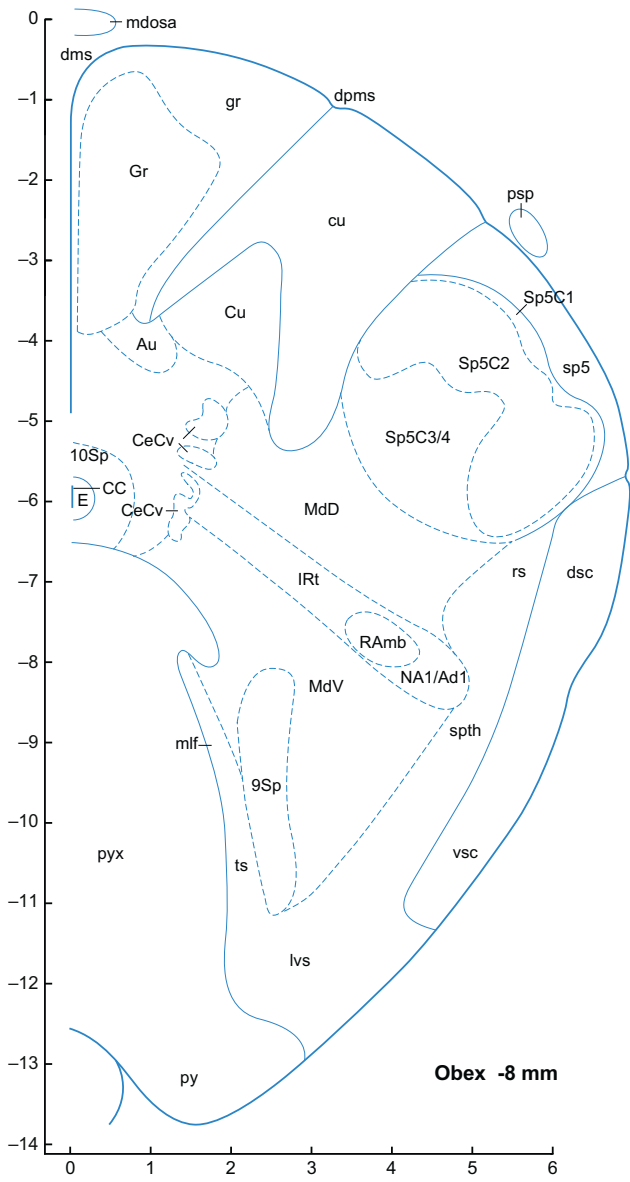


FIGURE 8.9 ■

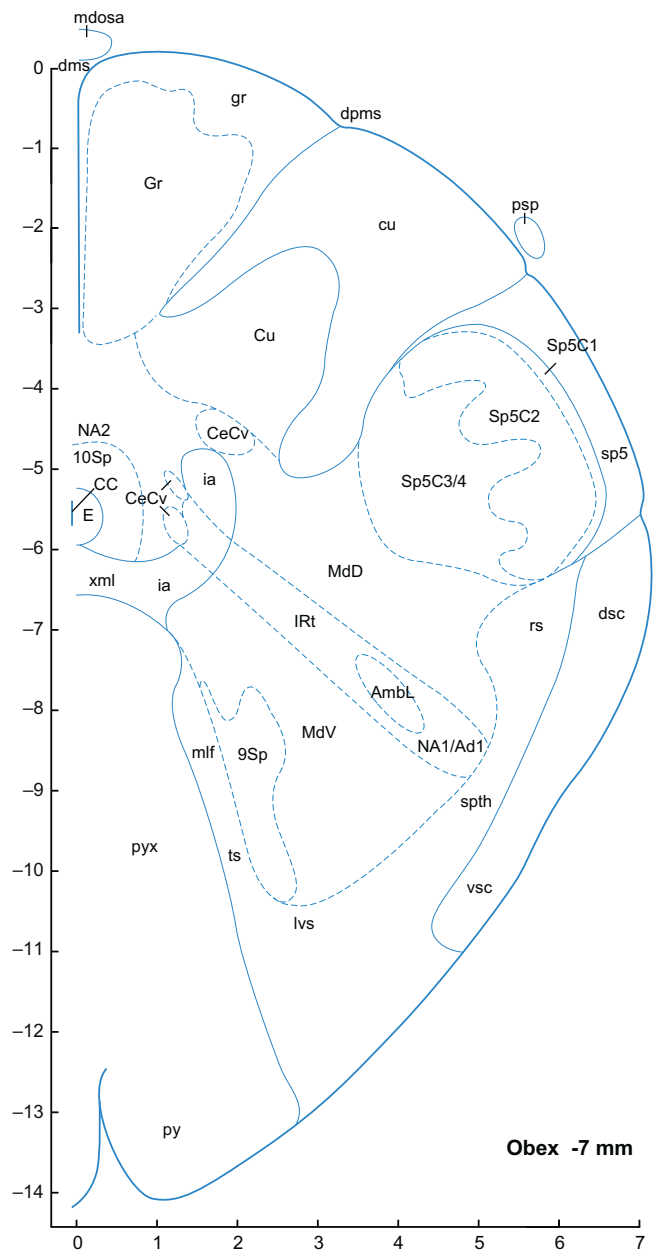


FIGURE 8.10 ■



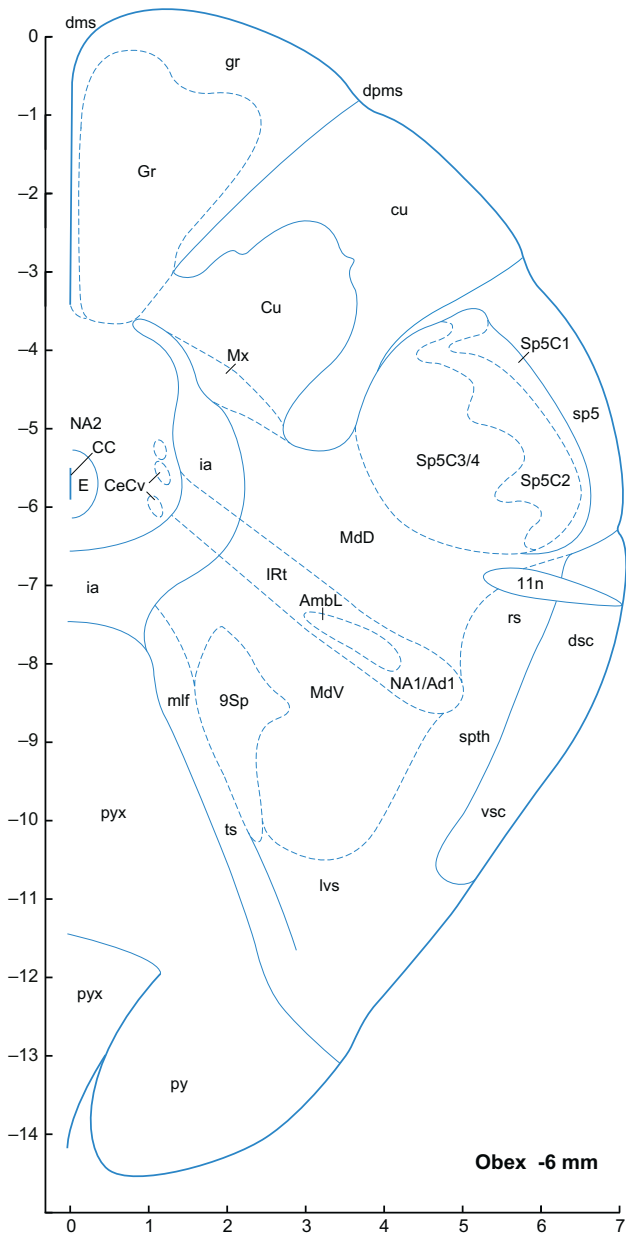


FIGURE 8.11 ■

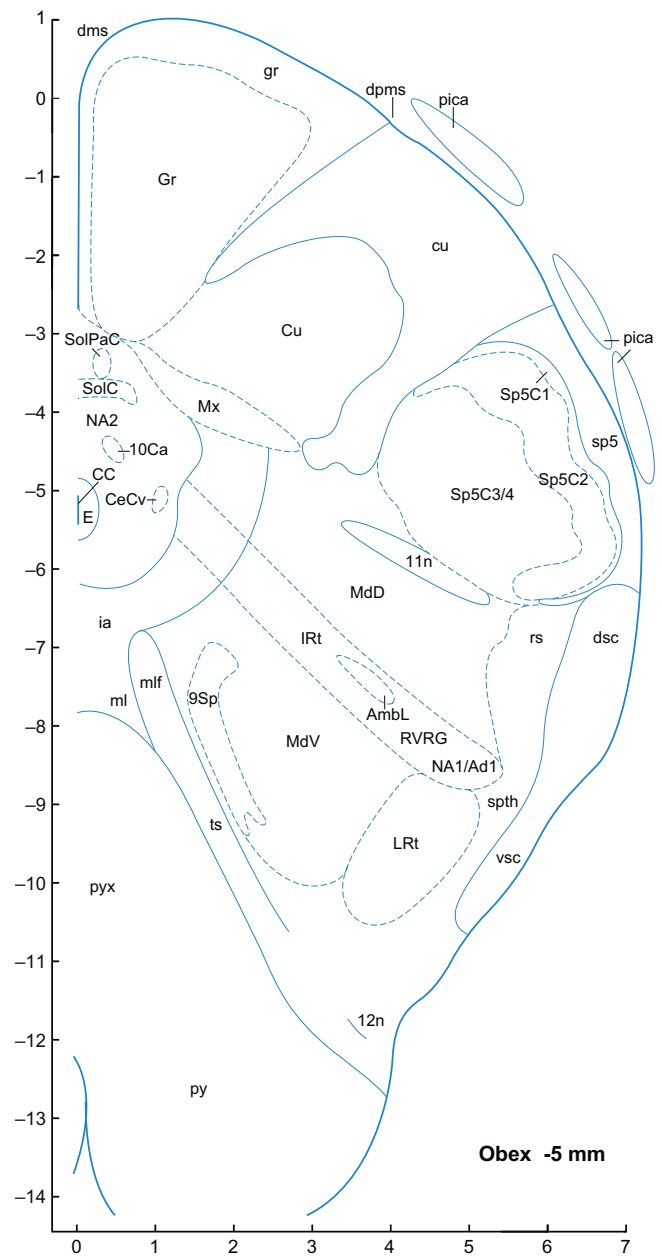


FIGURE 8.12 ■

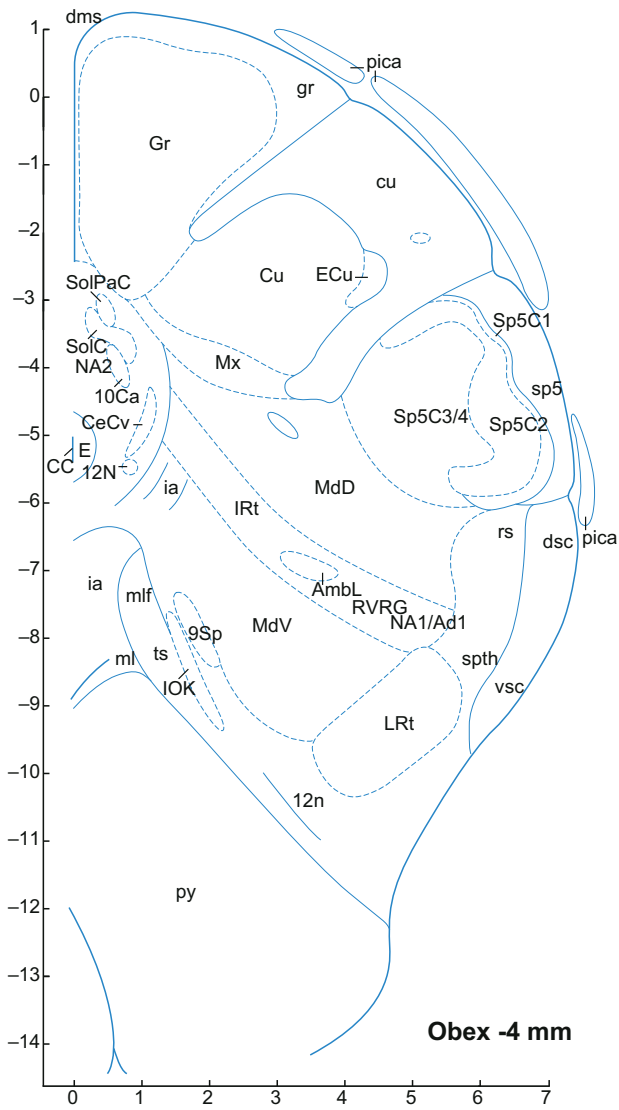


FIGURE 8.13 ■




FIGURE 8.14 ■

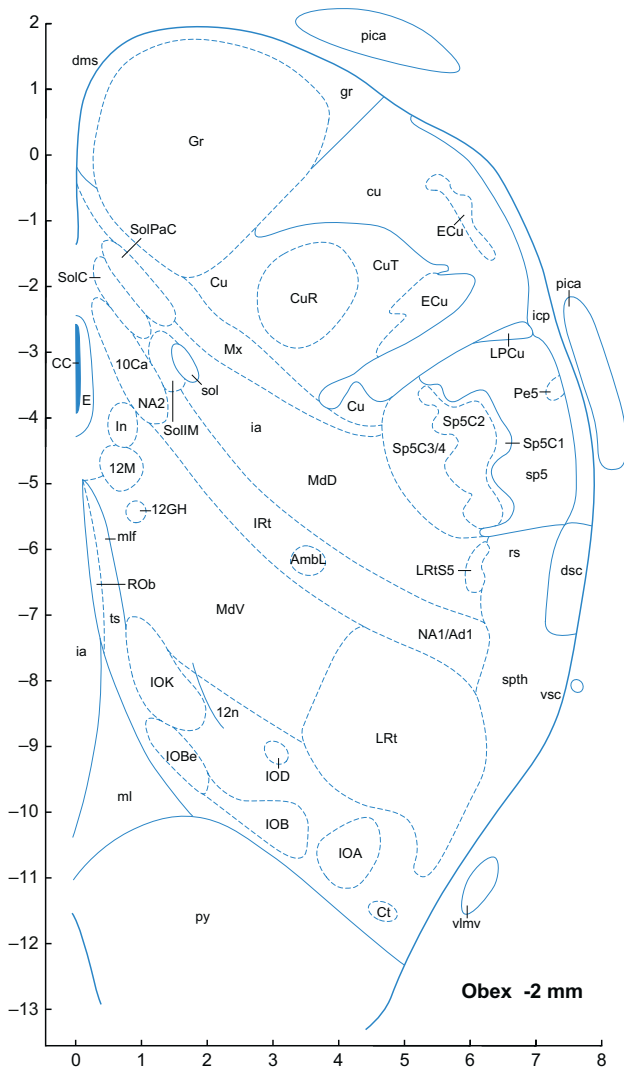


FIGURE 8.15 ■

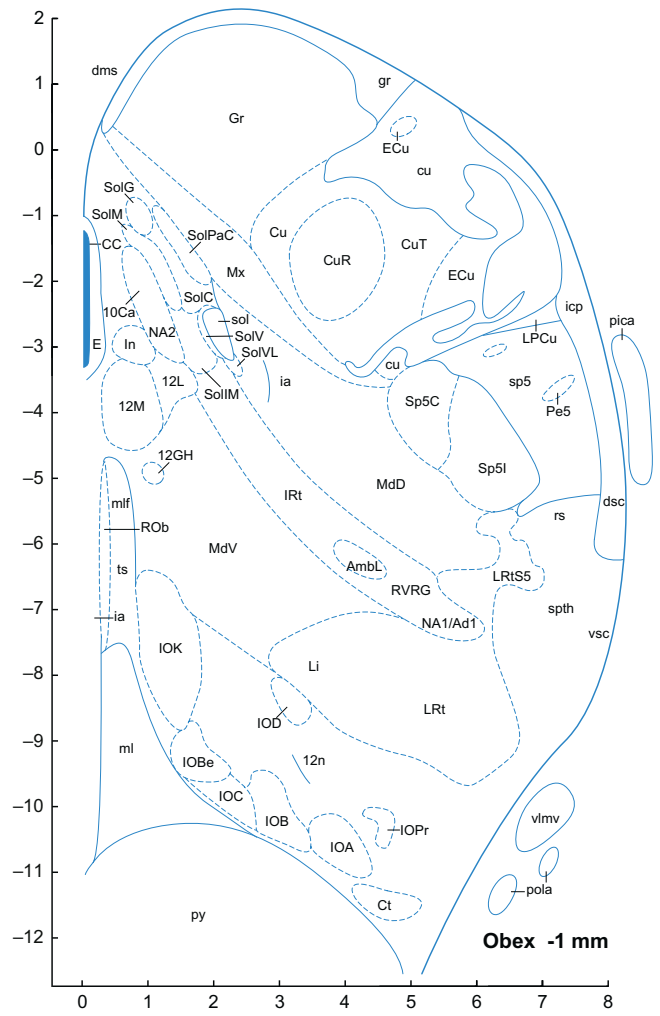


FIGURE 8.16 ■

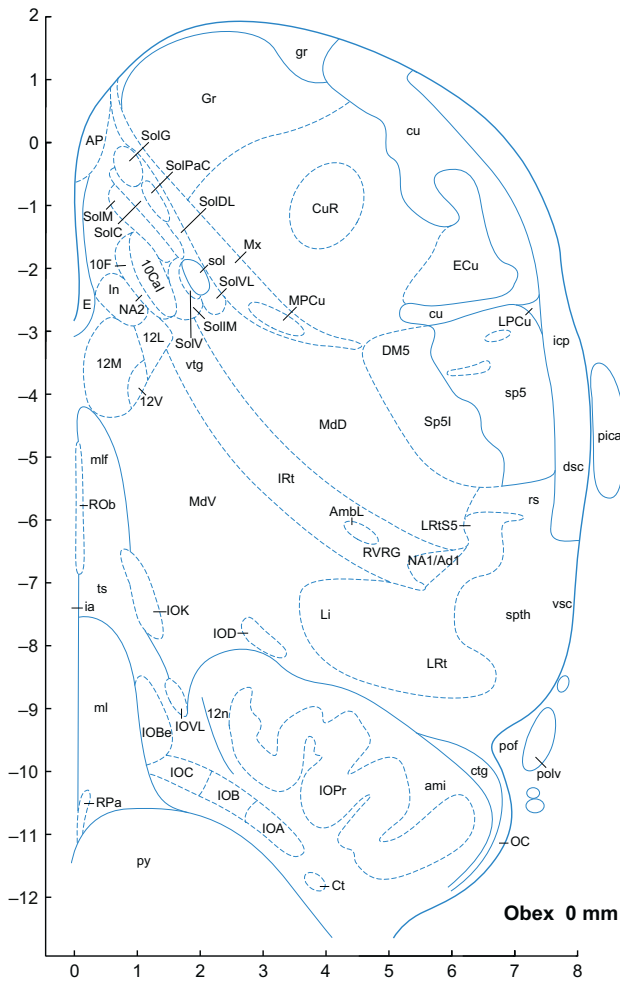


FIGURE 8.17 ■

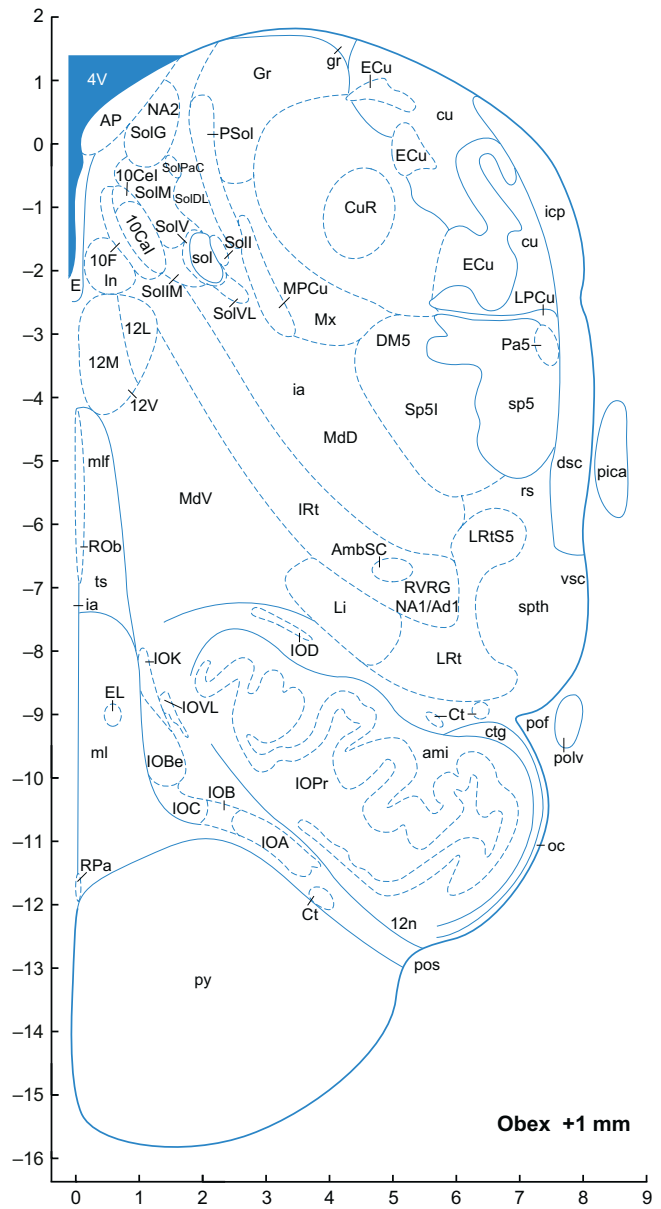


FIGURE 8.18 ■

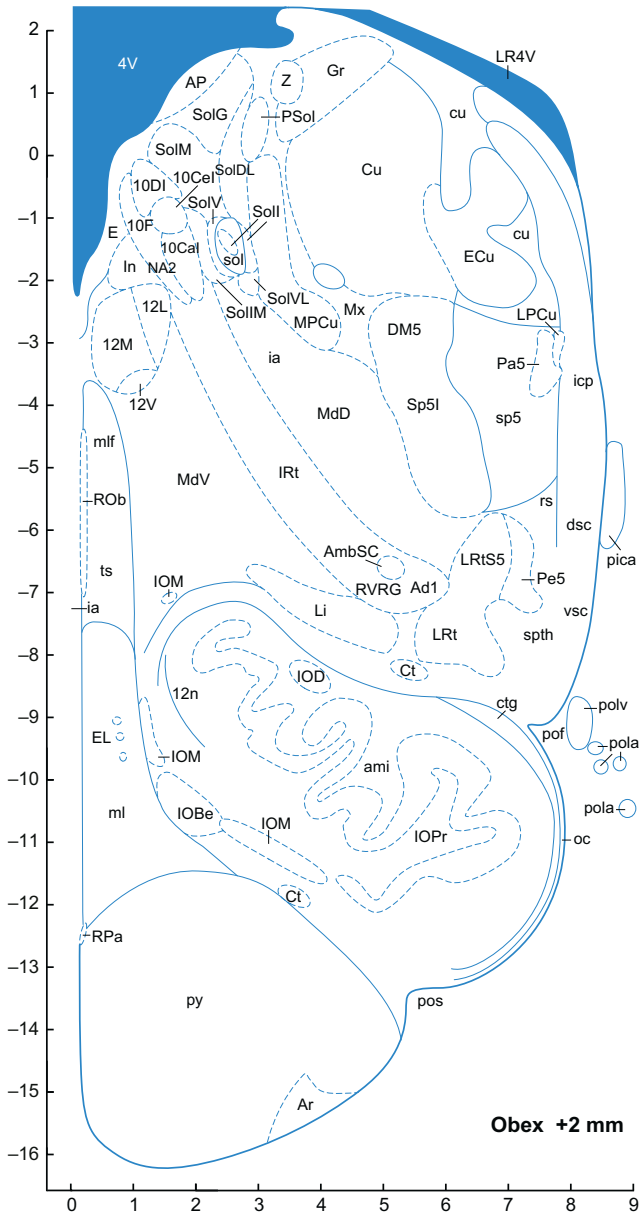


FIGURE 8.19 ■

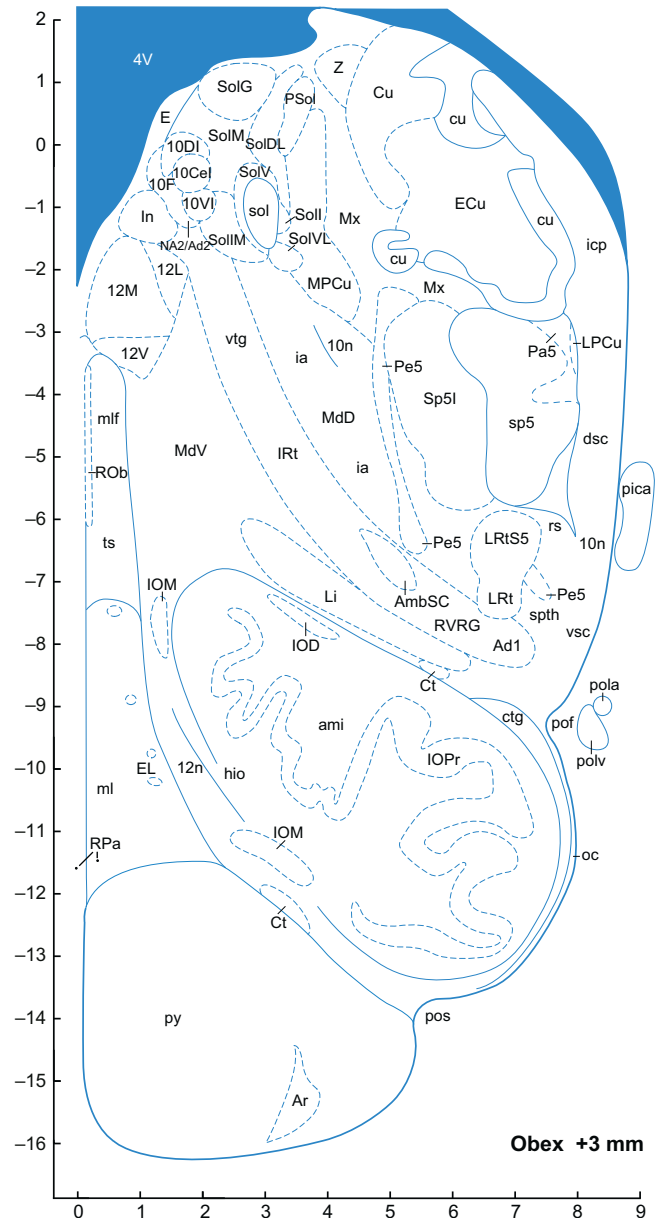


FIGURE 8.20 ■

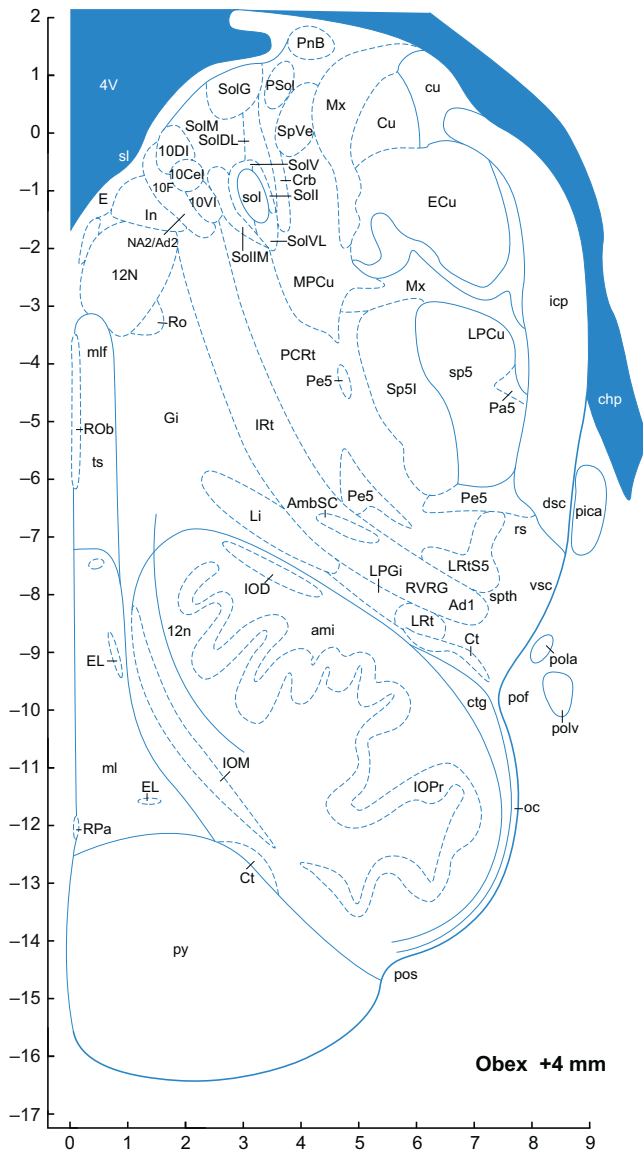


FIGURE 8.21 ■

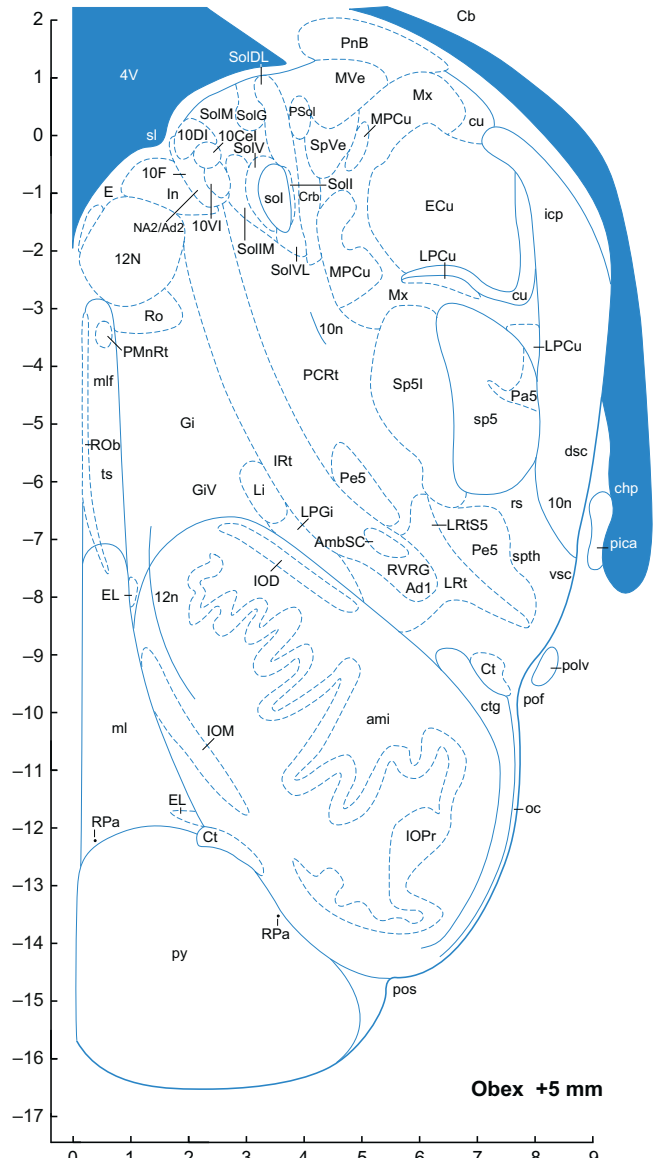


FIGURE 8.22 ■

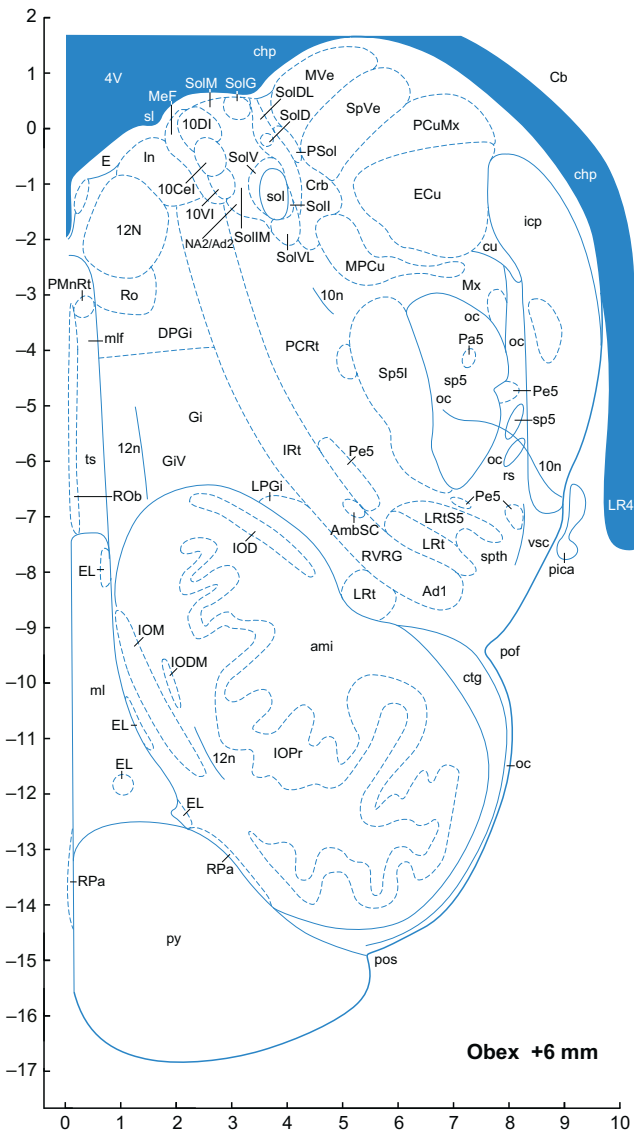


FIGURE 8.23 ■

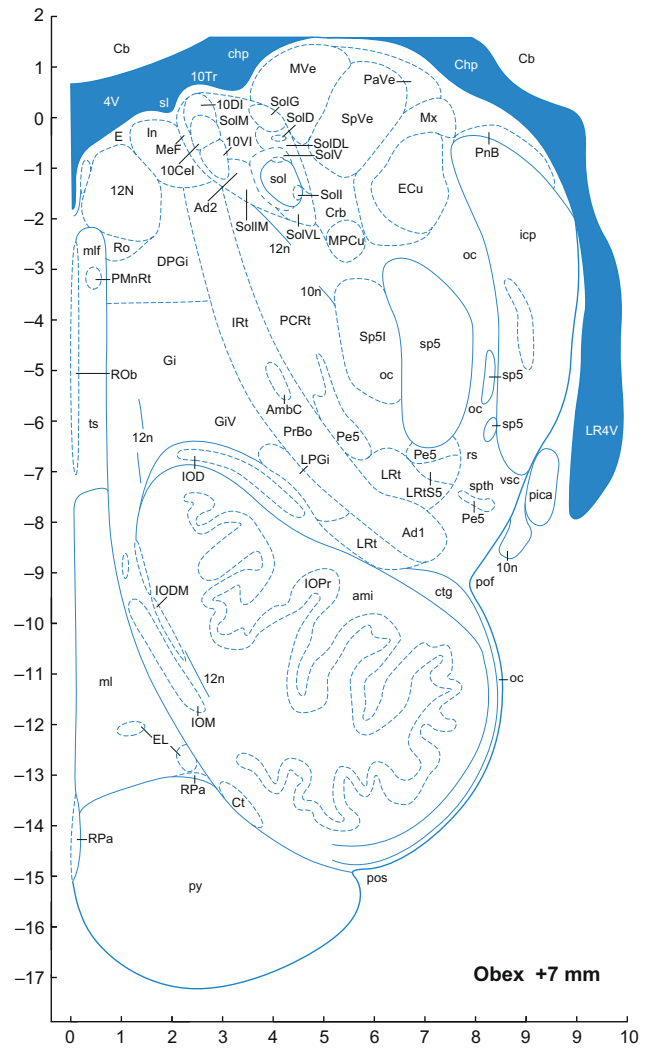


FIGURE 8.24 ■



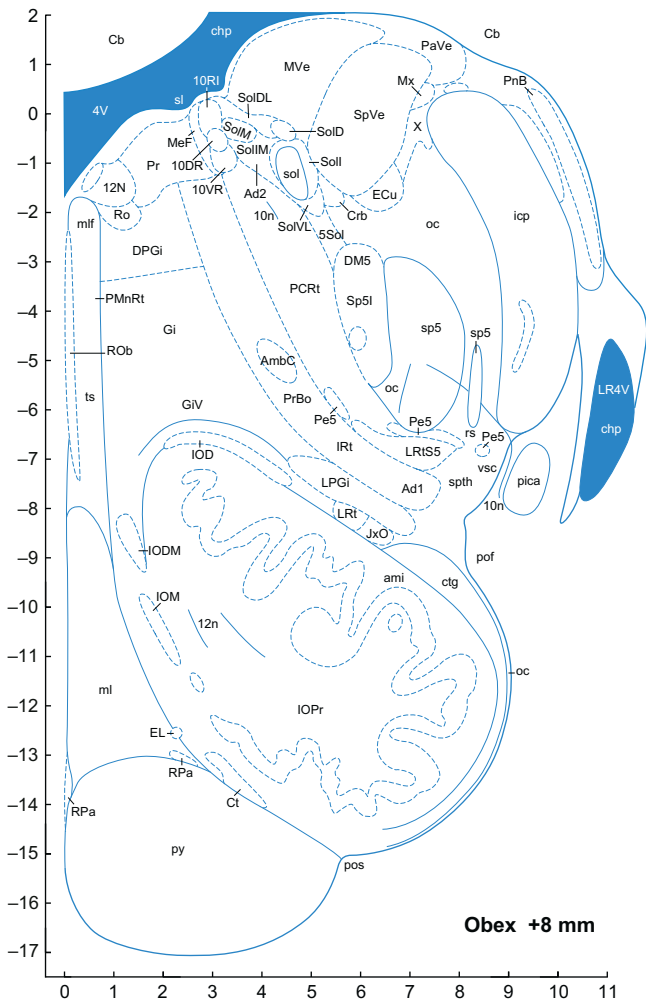


FIGURE 8.25 ■

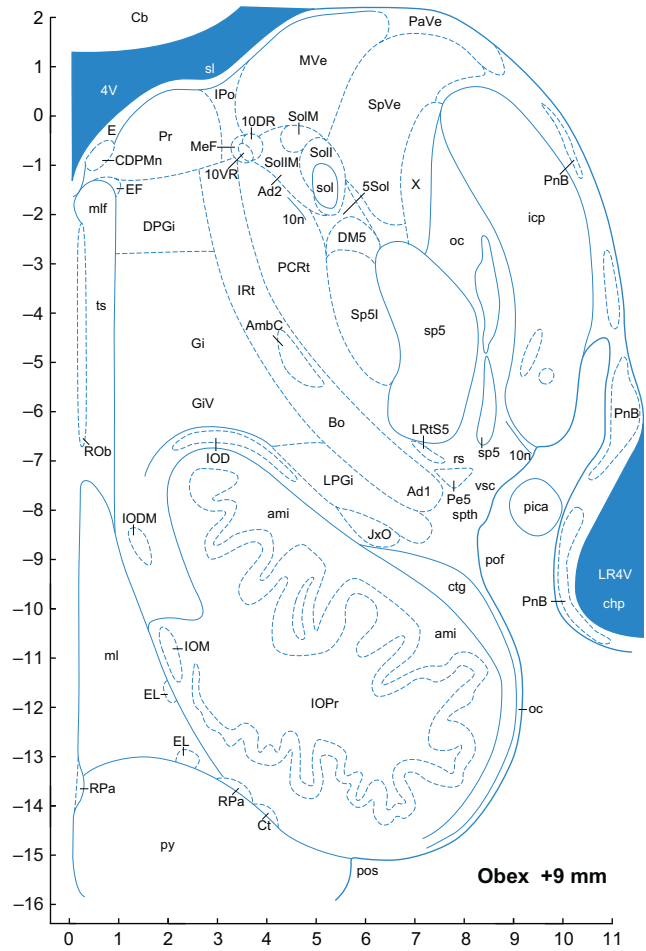


FIGURE 8.26 ■

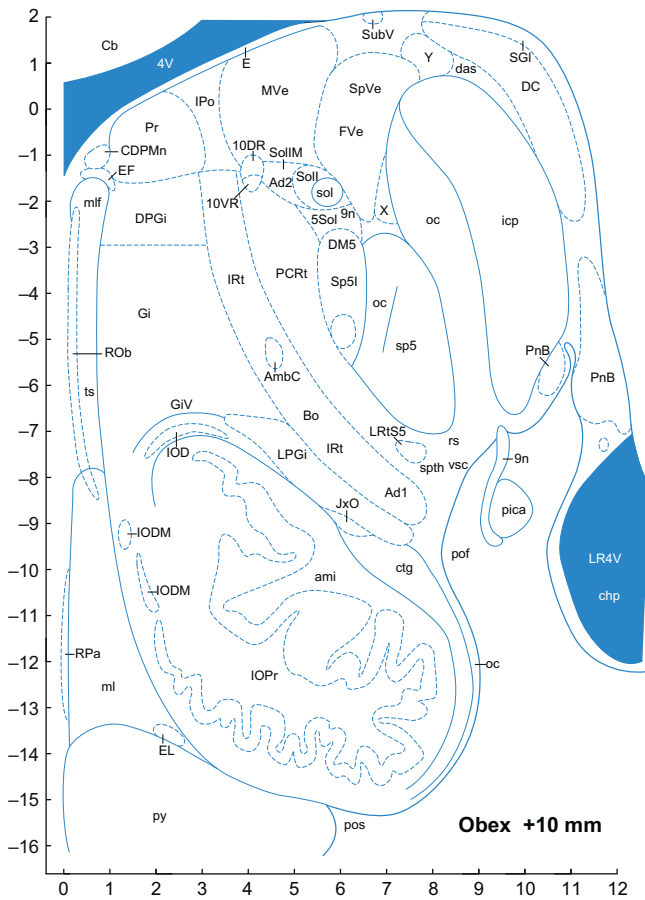


FIGURE 8.27 ■

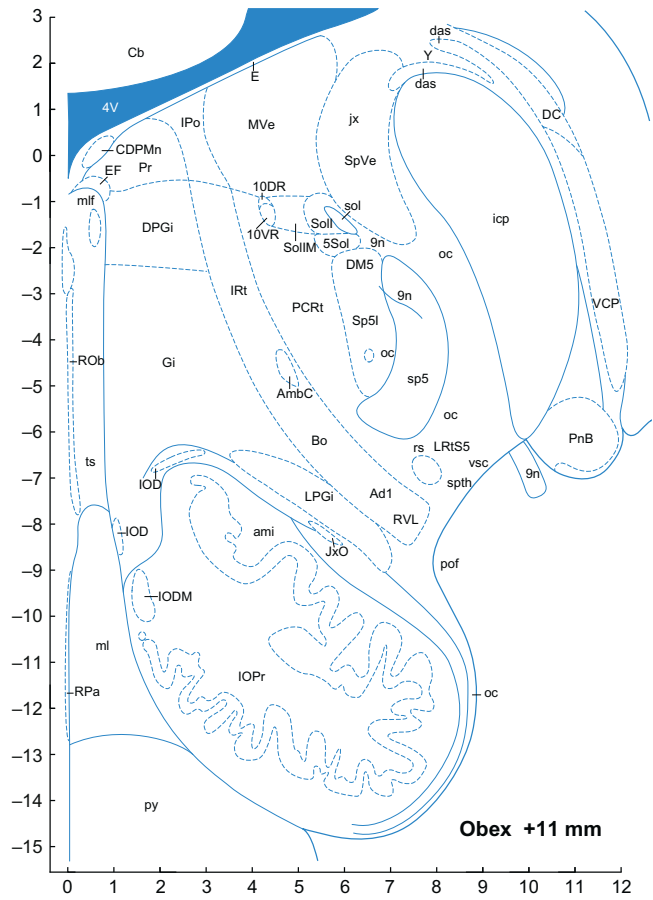


FIGURE 8.28 ■

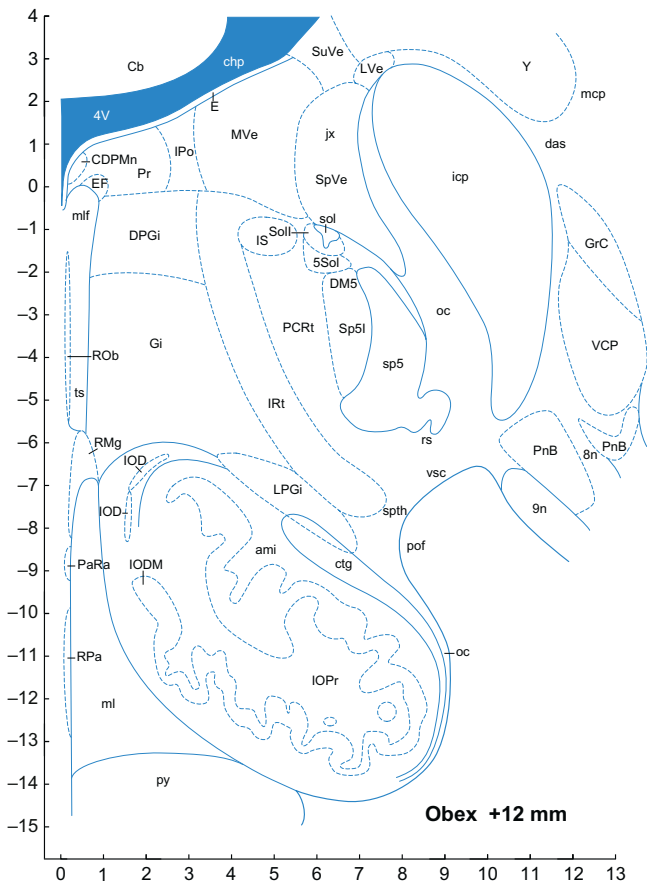


FIGURE 8.29 ■

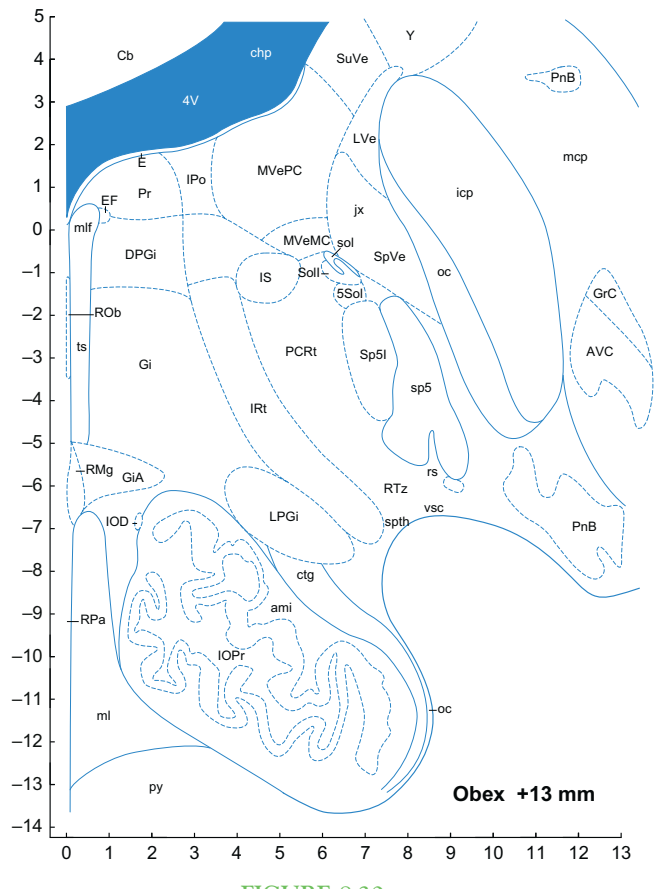


FIGURE 8.30 ■

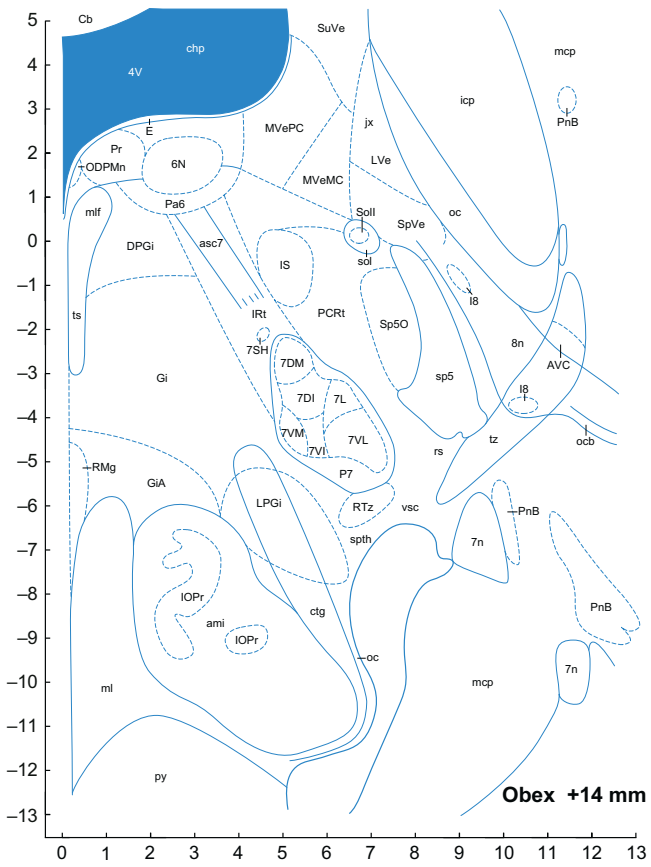


FIGURE 8.31 ■

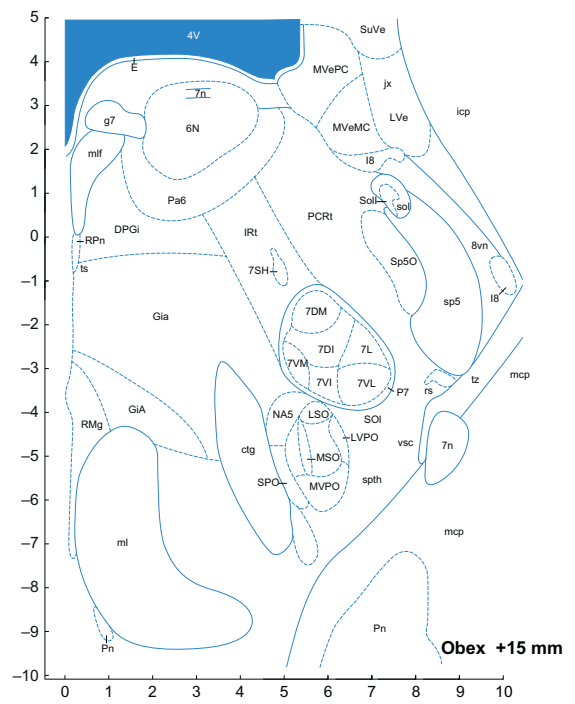


FIGURE 8.32 ■

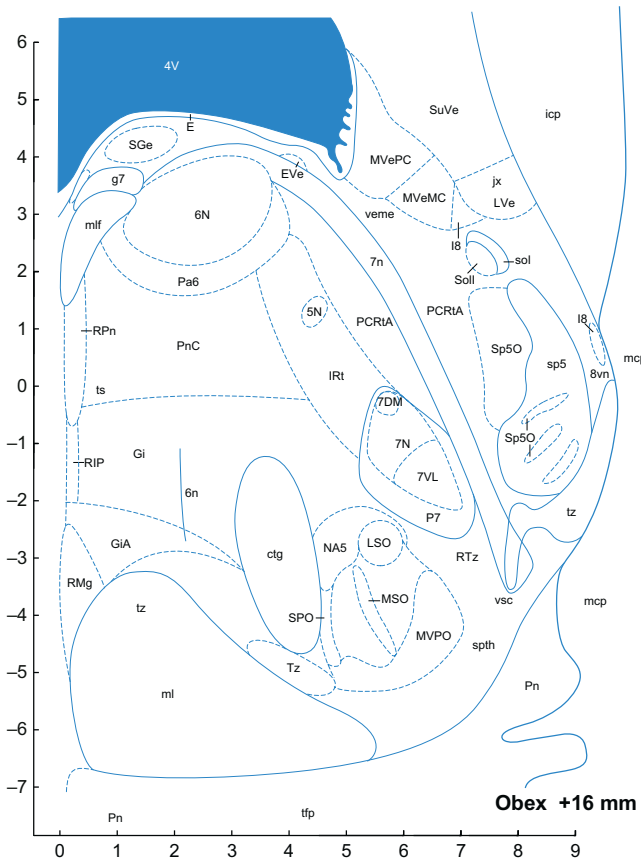


FIGURE 8.33 ■

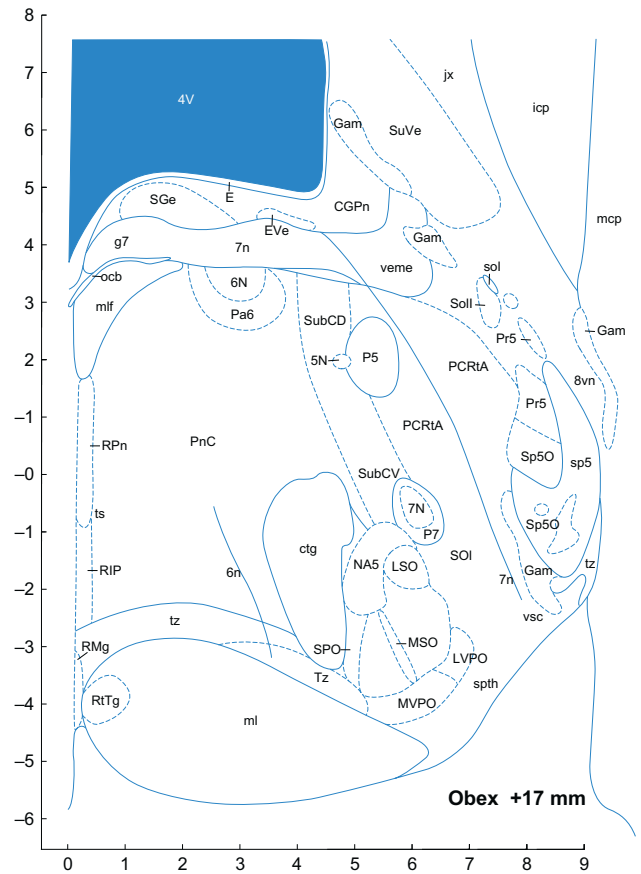


FIGURE 8.34 ■

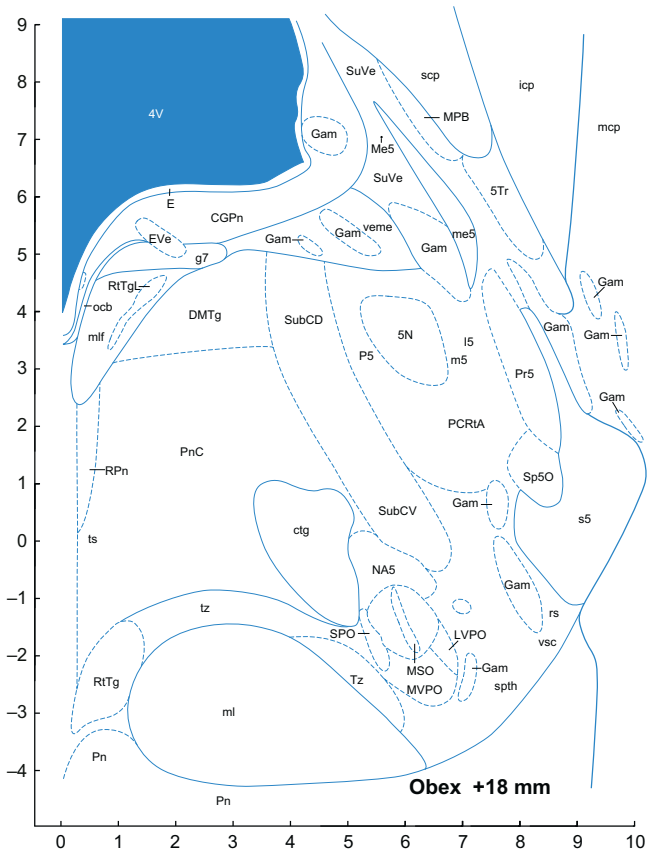


FIGURE 8.35 ■

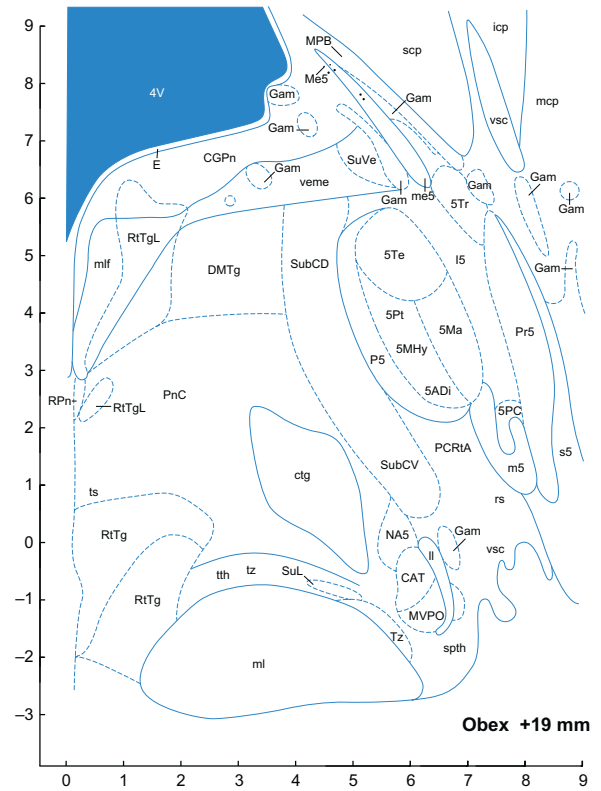


FIGURE 8.36 ■

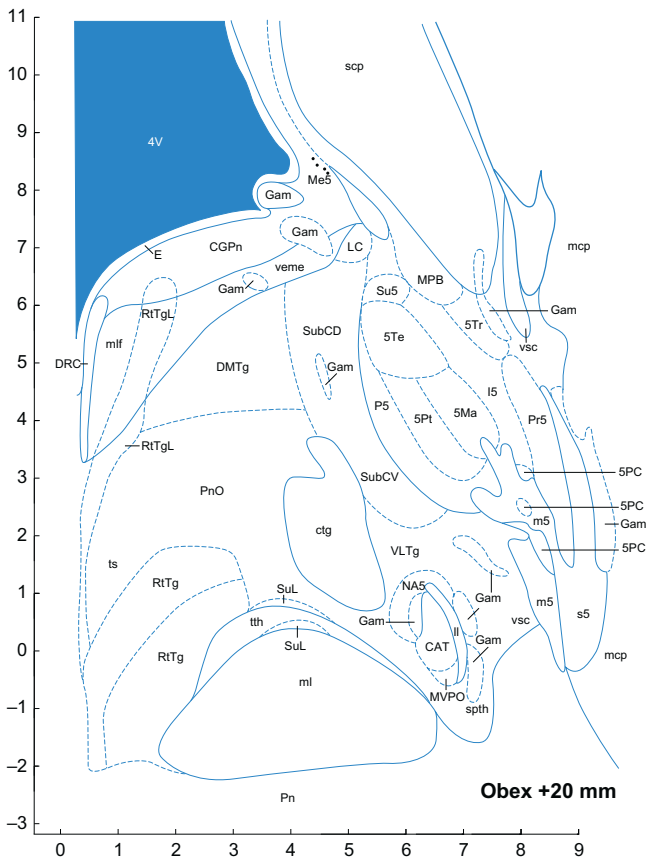


FIGURE 8.37 ■

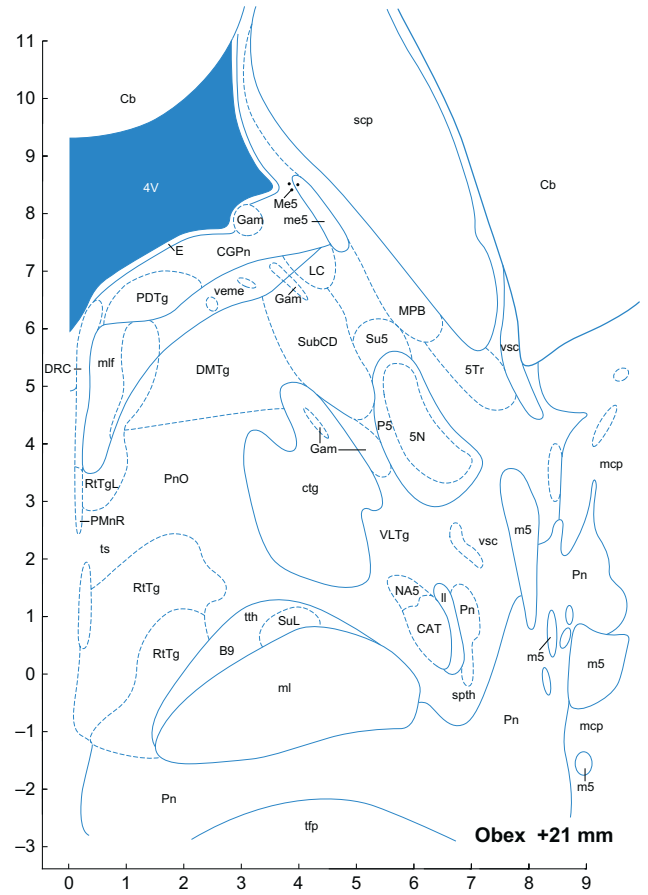


FIGURE 8.38 ■



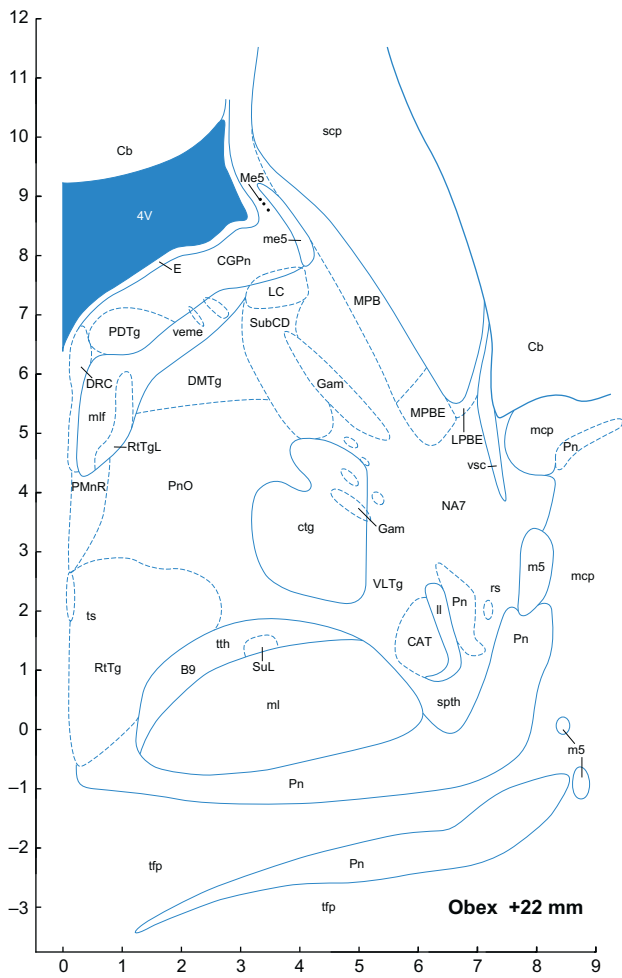


FIGURE 8.39 ■

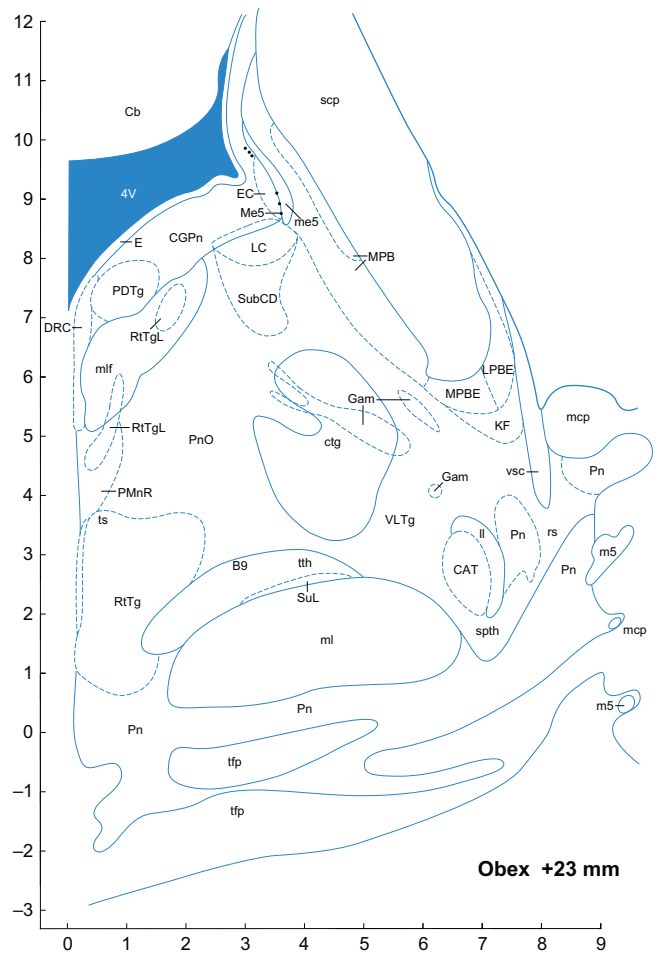


FIGURE 8.40 ■

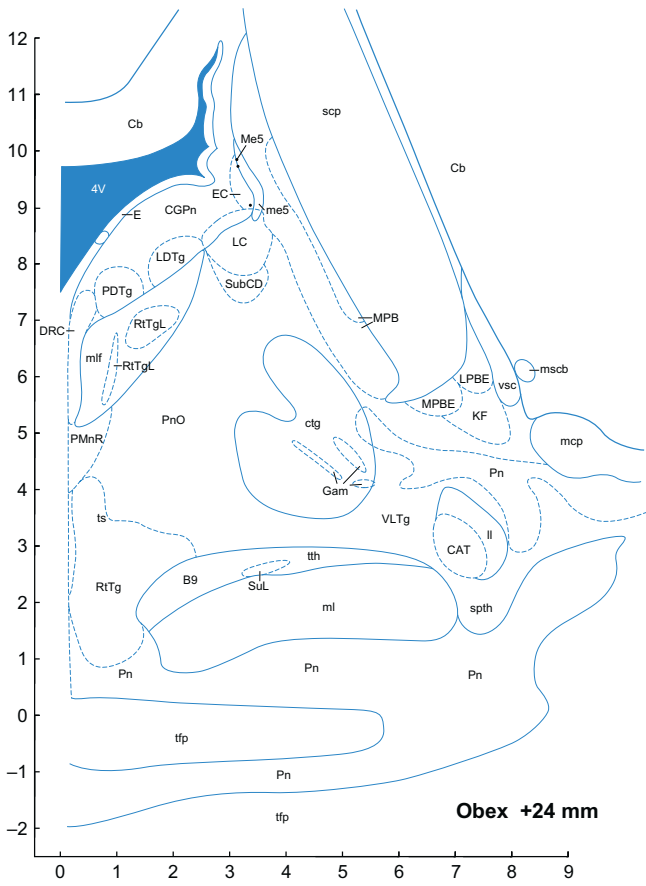


FIGURE 8.41 ■

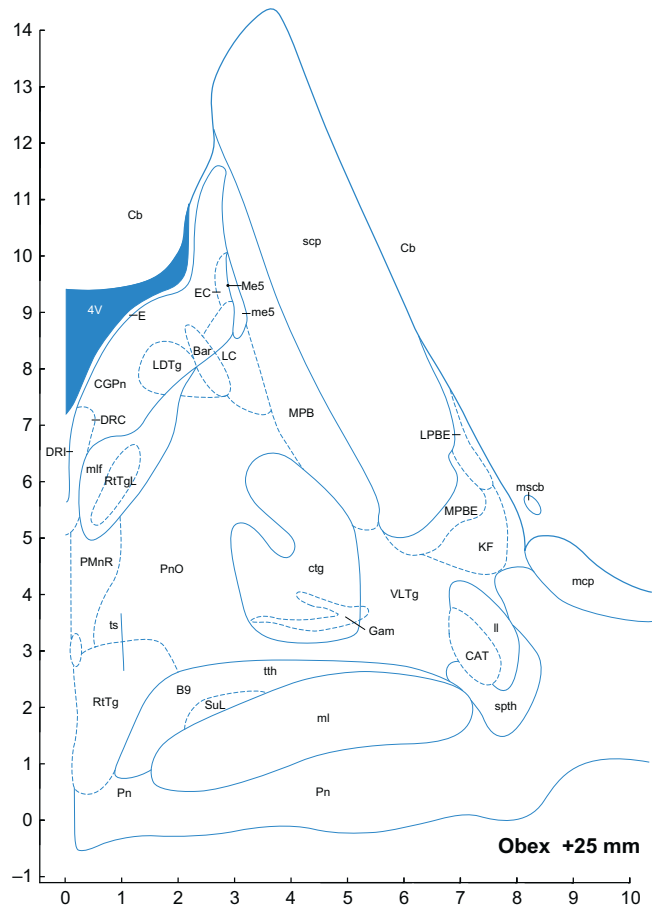


FIGURE 8.42 ■

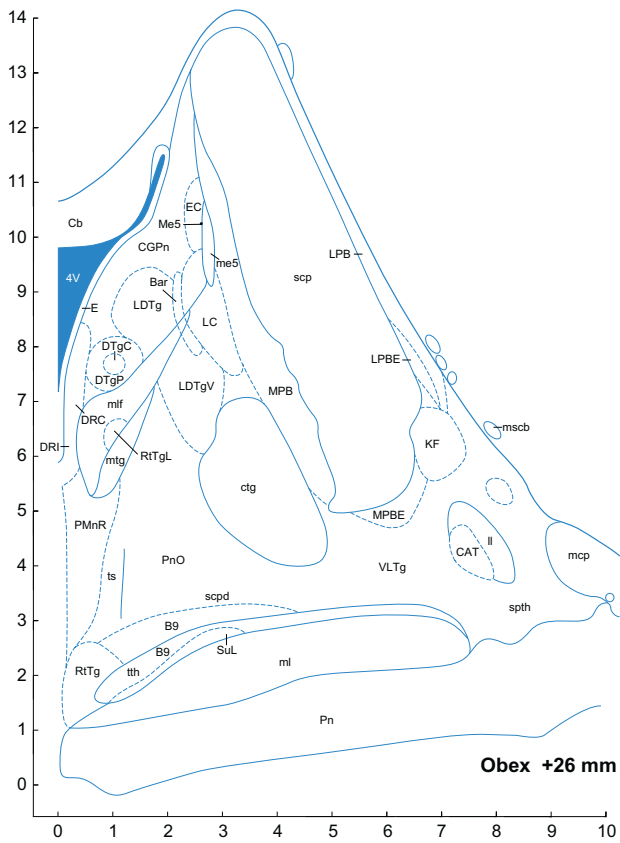


FIGURE 8.43 ■

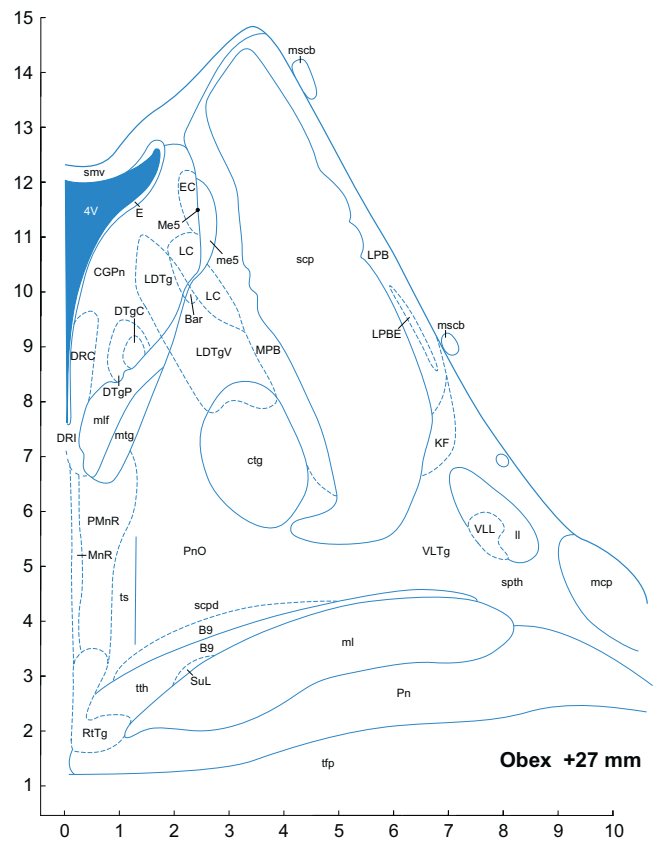


FIGURE 8.44 ■

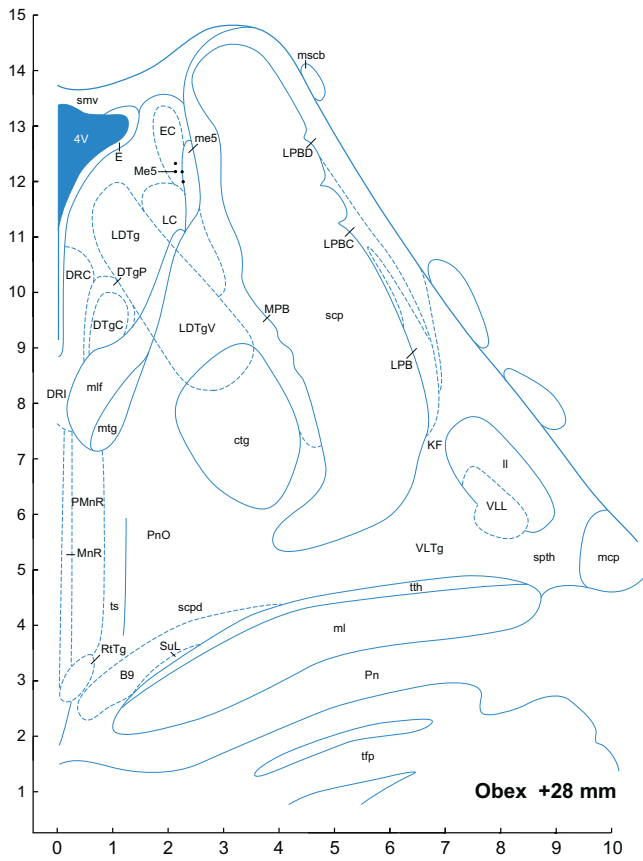


FIGURE 8.45 ■

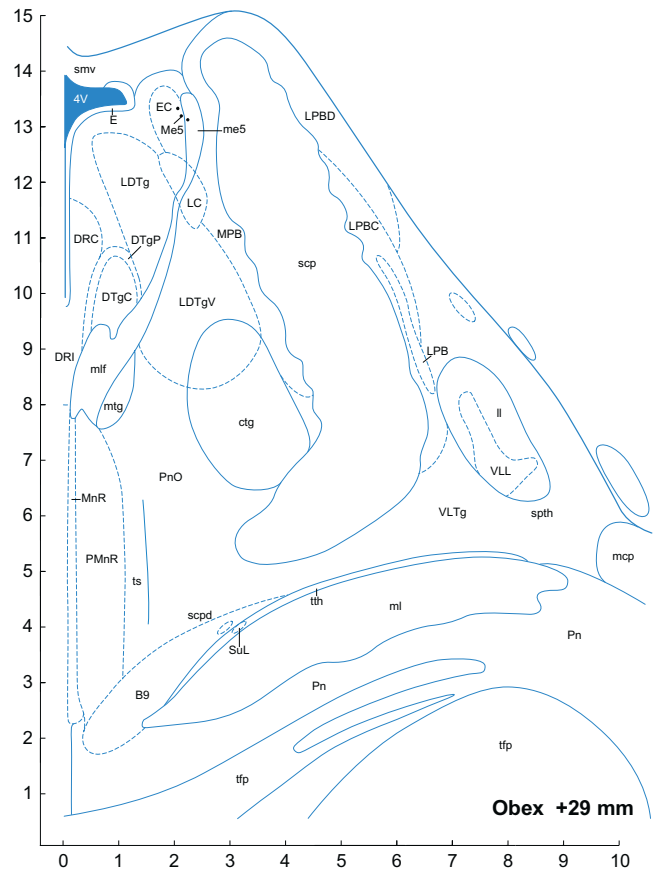


FIGURE 8.46 ■

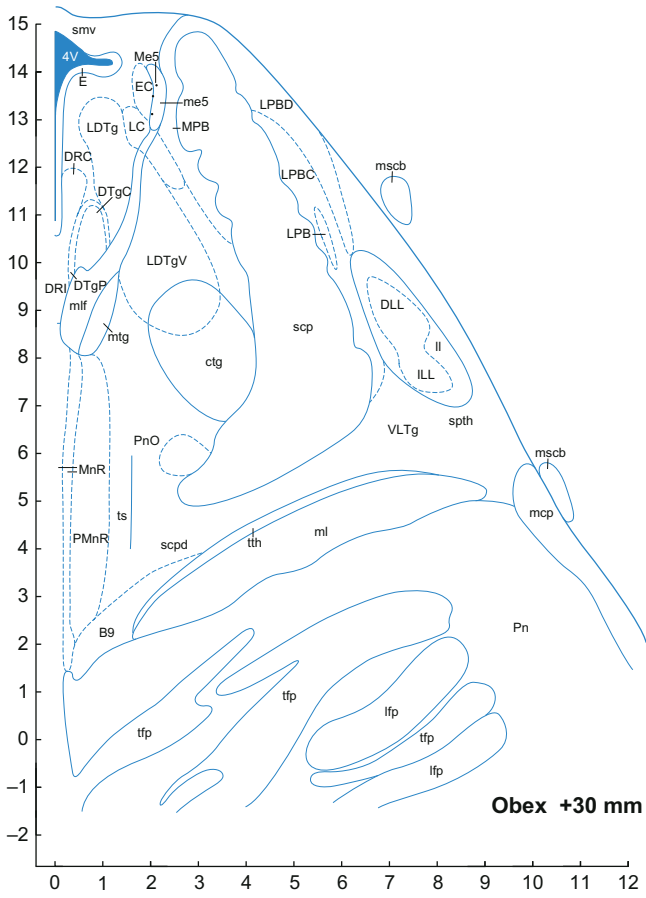


FIGURE 8.47 ■

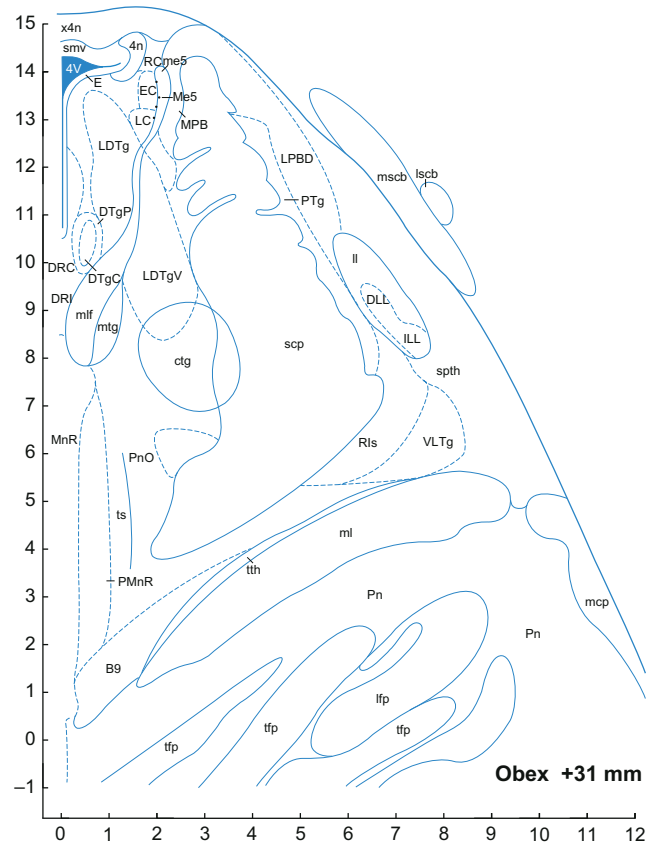


FIGURE 8.48 ■

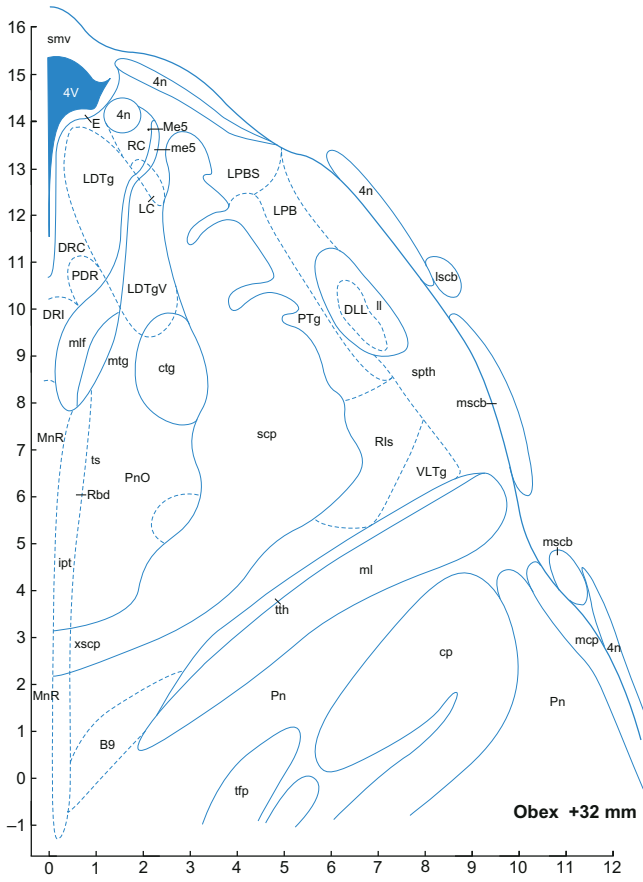


FIGURE 8.49 ■

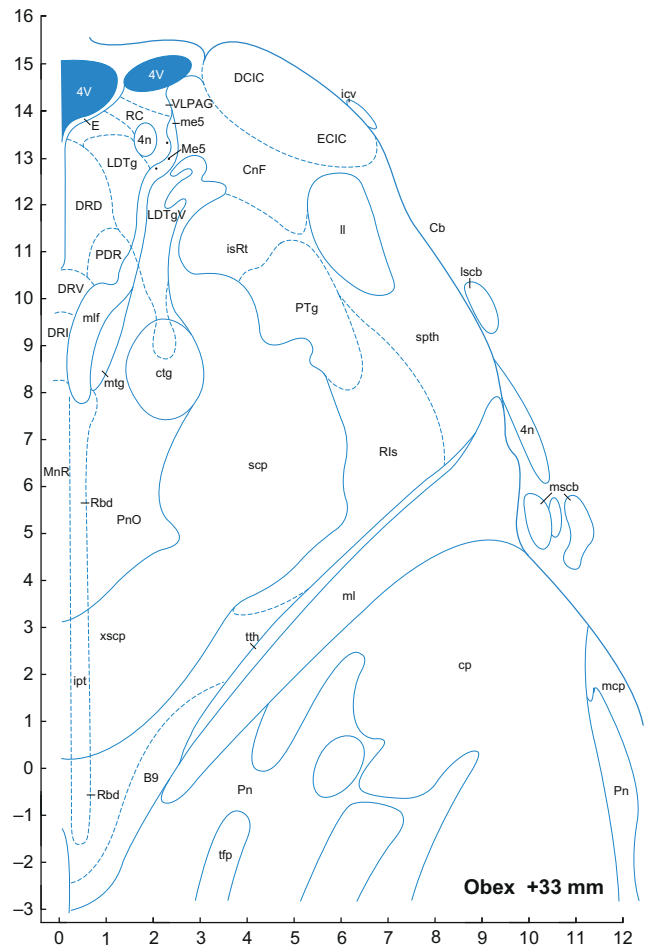


FIGURE 8.50 ■

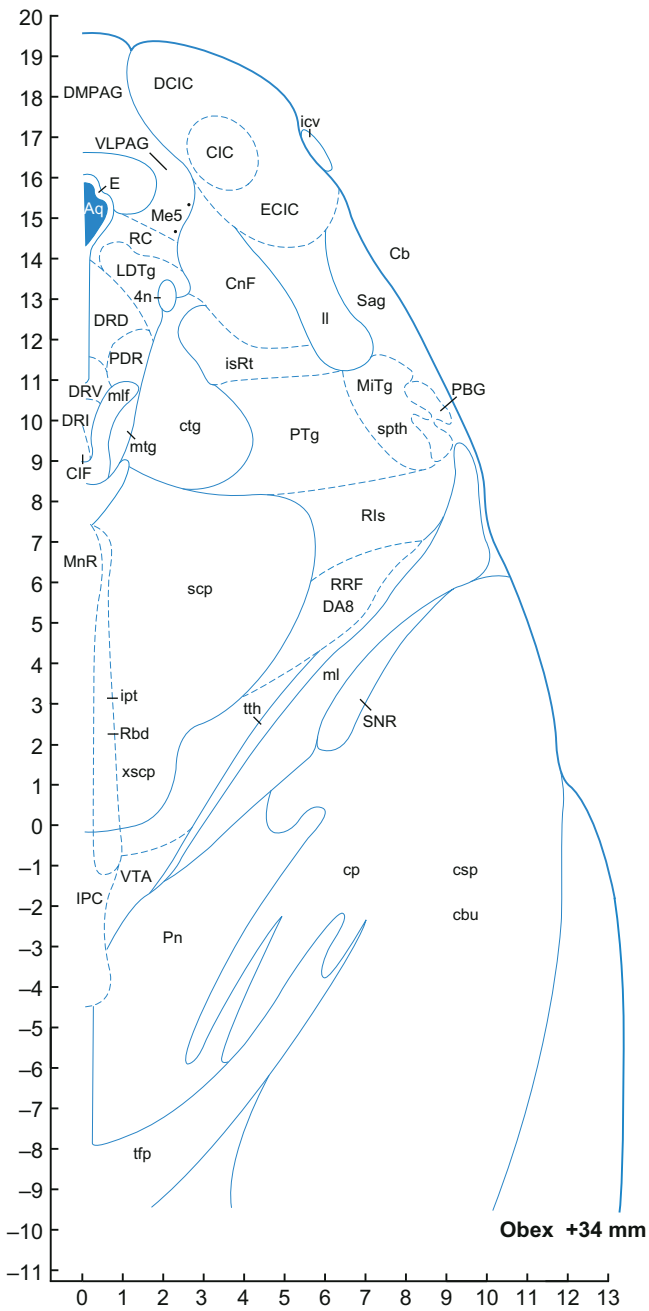


FIGURE 8.51 ■

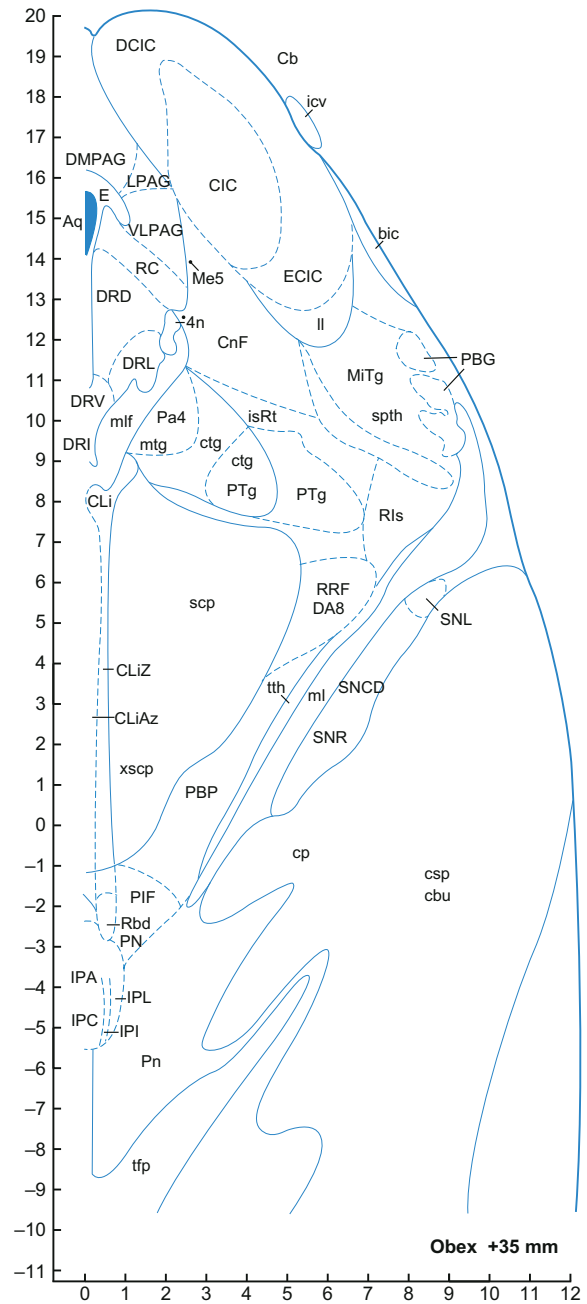


FIGURE 8.52 ■

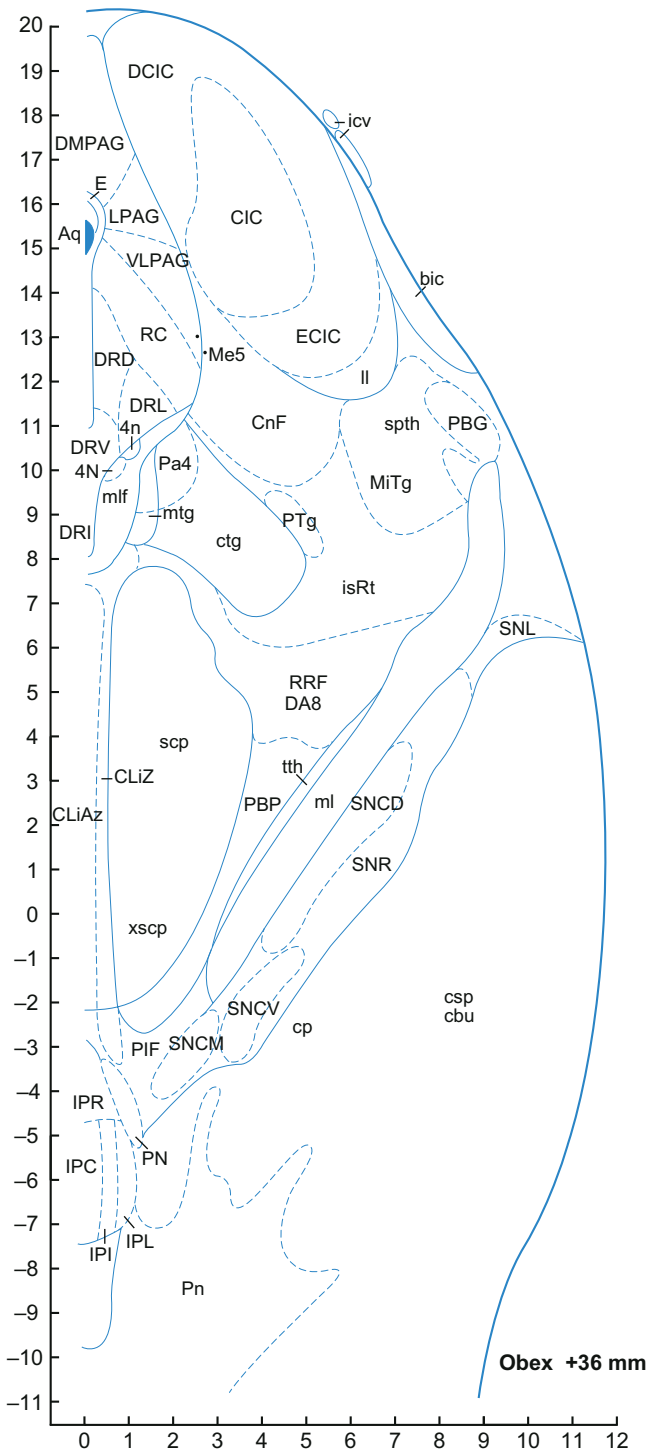


FIGURE 8.53 ■

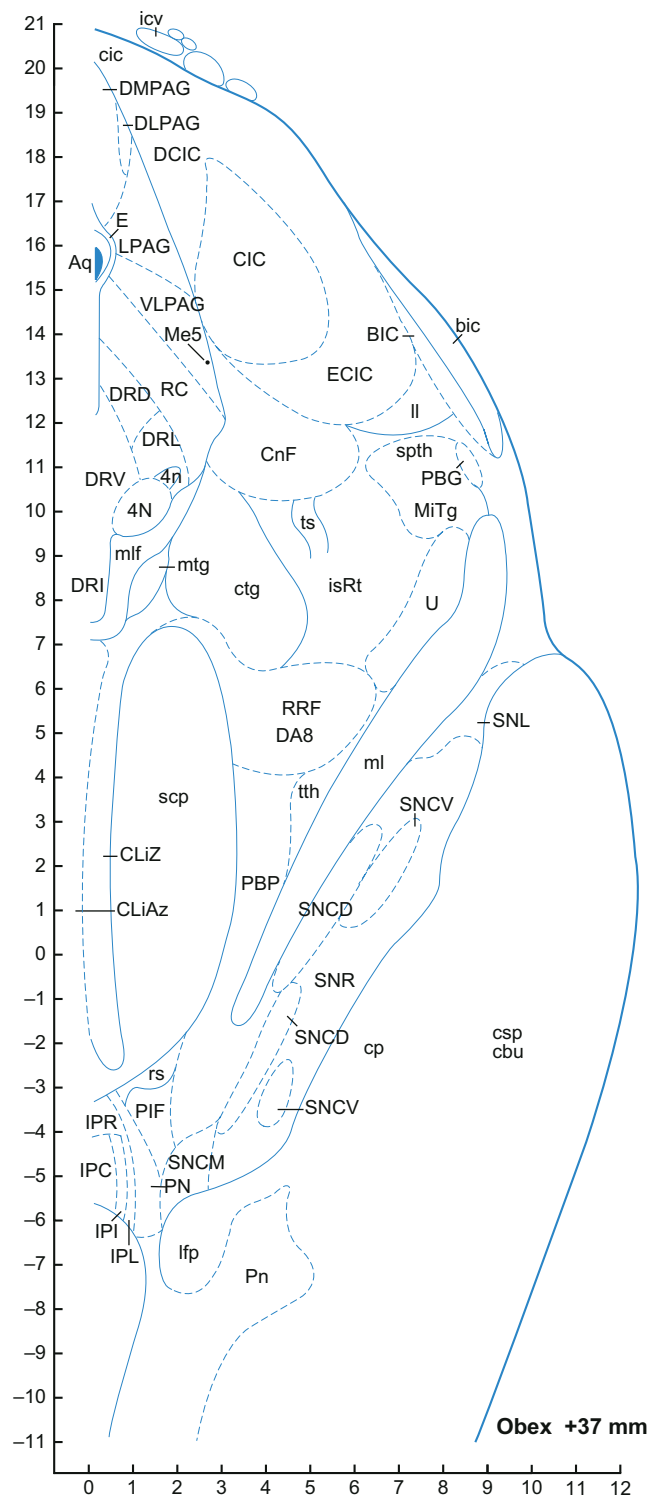


FIGURE 8.54 ■





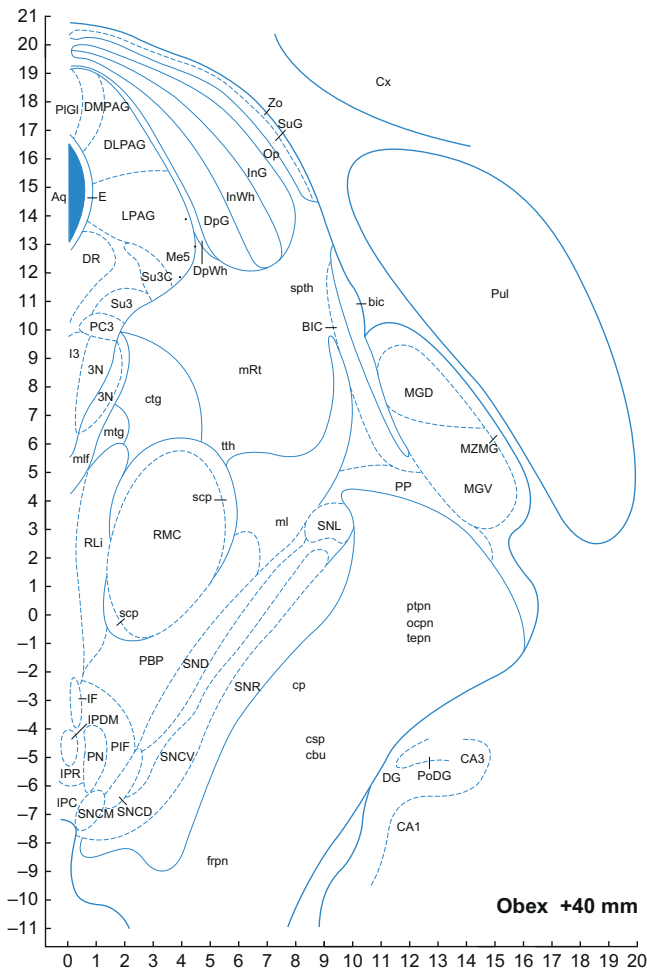


FIGURE 8.57 ■

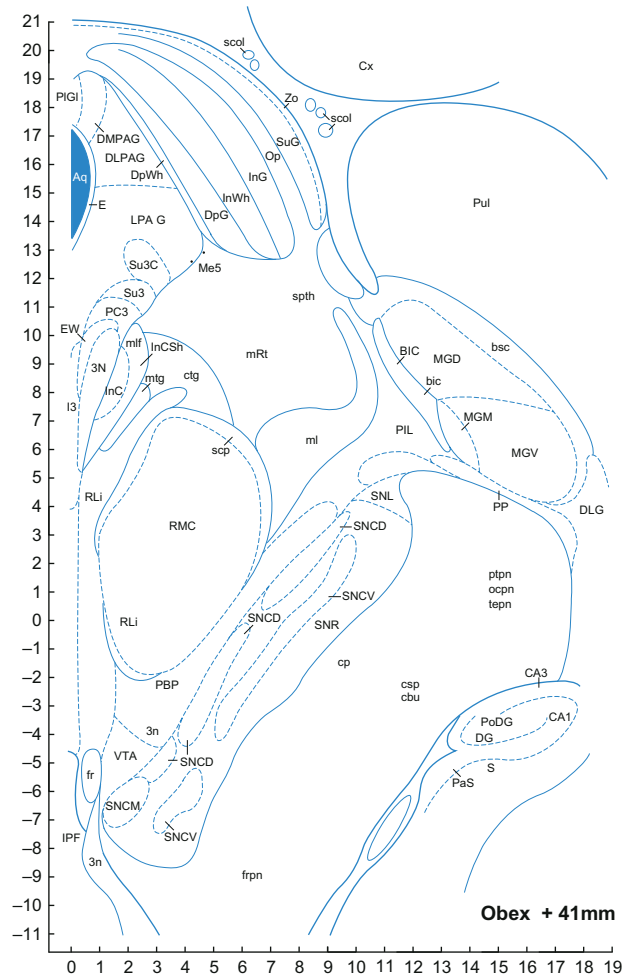


FIGURE 8.58 ■

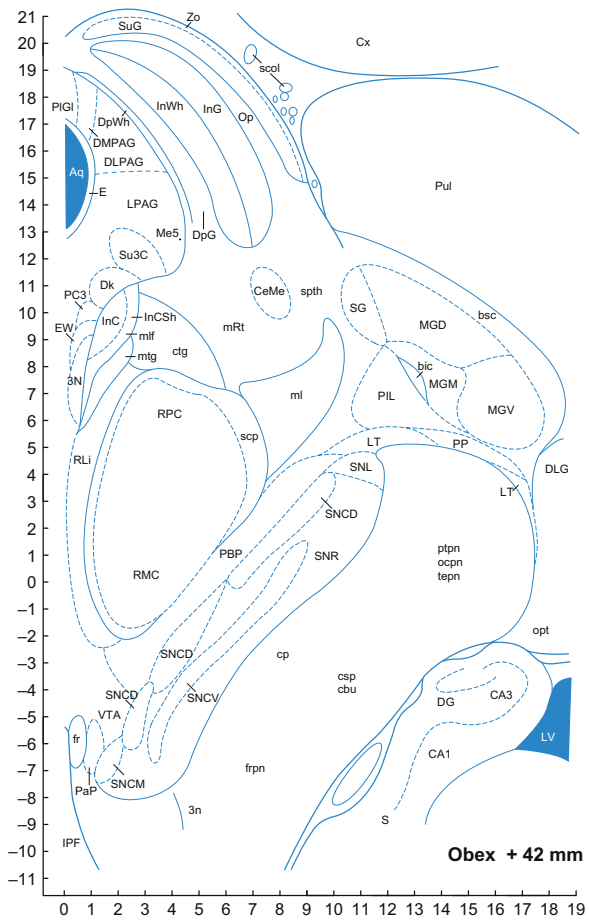


FIGURE 8.59 ■

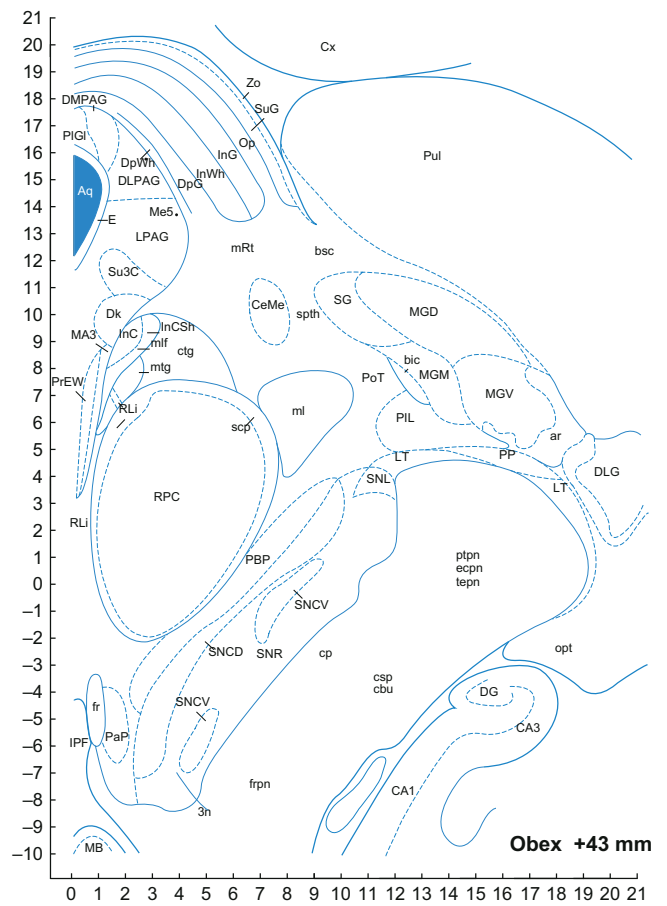
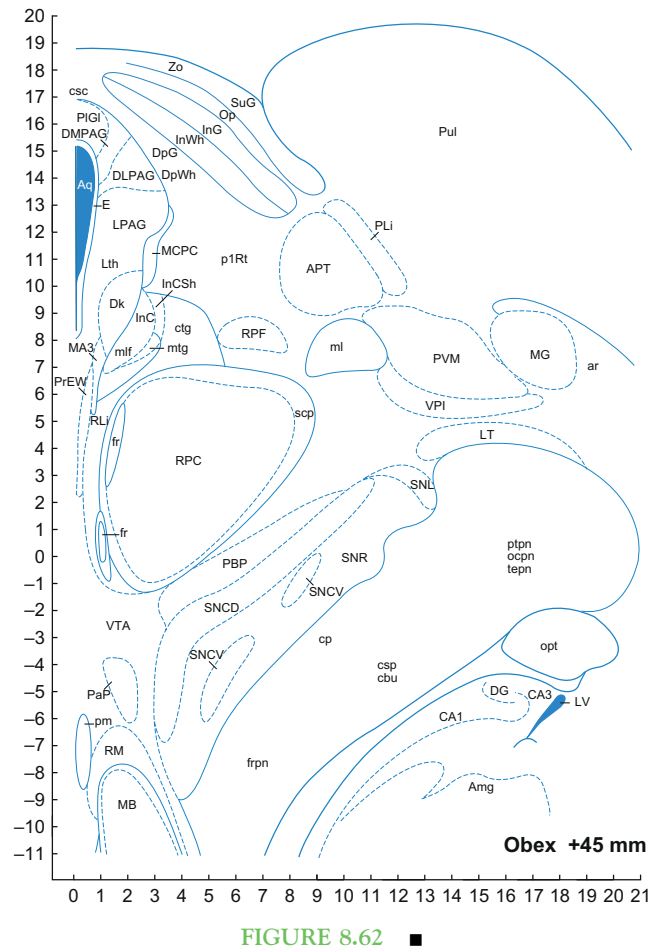
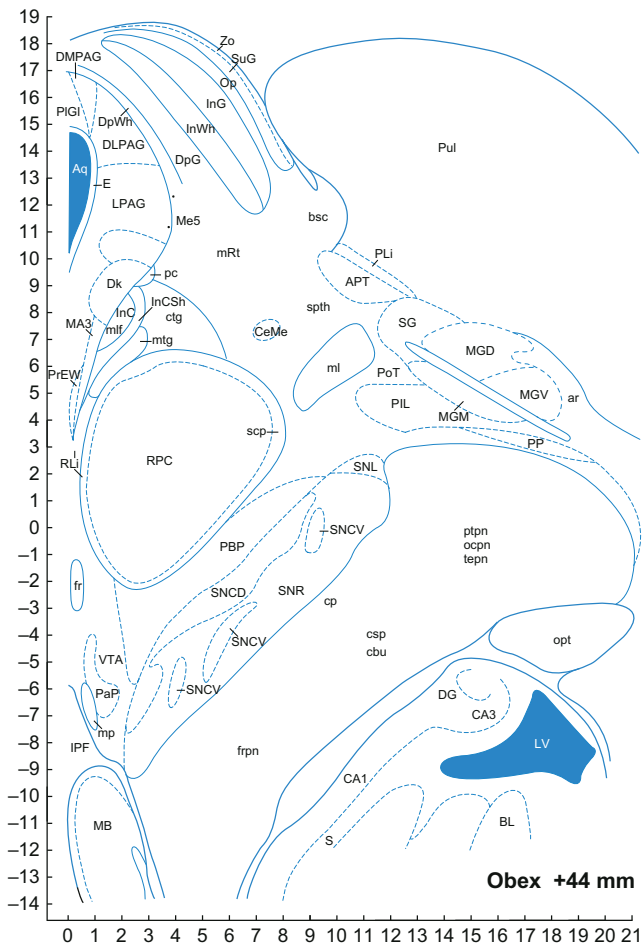


FIGURE 8.60 ■



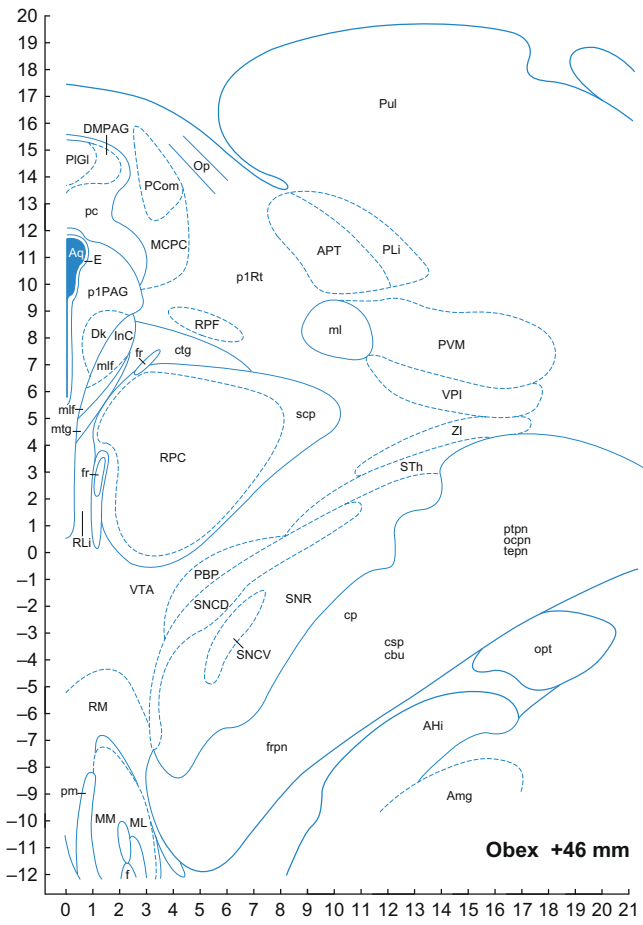


FIGURE 8.63 ■

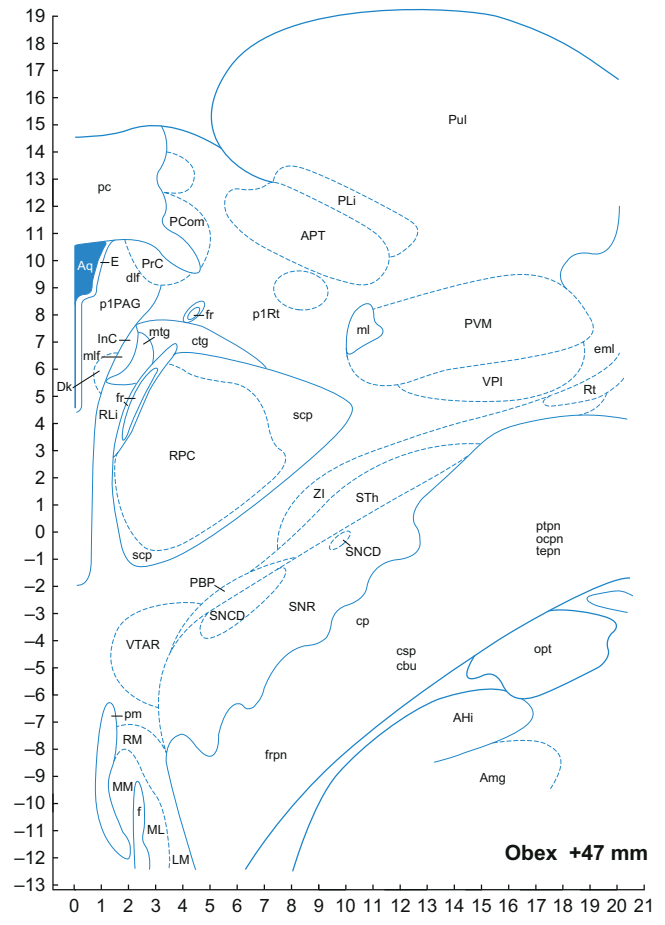


FIGURE 8.64 ■

## AUTONOMIC REGULATORY CENTERS

### Dorsal Motor Nucleus of Vagus

Huang and colleagues (1993a, 1993b) published a combined cyto- and chemoarchitectonic analysis depicting the human homologs of the subnuclei of the dorsal motor nucleus of vagus (10N) (Figures 8.12–8.28). The caudal pole of the dorsal motor nucleus is found at the pyramidal decussation dorsolateral to the central canal (caudal to Figure 8.11). At this level, it is a loose group of strongly AChE-positive cells. The cell bodies in 10N are prominent on a background of otherwise medium staining. This is in contrast with the hypoglossal nucleus, where the intense reaction in the neuropil obscures the equally intensely reactive cell bodies. The 10N is separated from the hypoglossal nucleus by the intercalated nucleus. The 10N almost reaches the ventricular epithelium at the level of the area postrema (Figure 8.17). It recedes from the ventricular surface accompanying the solitary nucleus, rostral to the hypoglossal nucleus. A cell-poor and AChE-negative fringe flanks the medial aspect of 10N. A few cells can be noticed within this zone, a number of which are pigmented and positive for AChE and tyrosine hydroxylase (A2 cell group). Rostrally, 10N persists as a minor medial companion to the ventrolaterally migrating solitary complex (Figures 8.13–8.28). The compact rostral tip of the AChE-reactive 10N is succeeded by the salivatory nucleus – a scattering of AChE-positive neurons that persists until nearly the level of the exiting fascicles of the facial nerve (Figure 8.31).

Several chemoarchitectonic studies demonstrated a high concentration of receptors for somatostatin (Carpentier et al., 1996a, 1996b), nicotinic acetylcholine (Duncan et al., 2008), serotonin (Paterson and Darnall, 2009), cannabinoid (Glass et al., 1997), D2 and D4 dopamine (Hyde et al., 1996), and neuropeptide FF2 (Goncharuk and Jhamandas, 2008). In the human 10N, cells containing adrenomedullin (Macchi et al., 2006), met-enkephalin (Covenas et al., 2004), neurokinin (Covenas et al., 2003), and bombesin (Lynn et al., 1996) have been found. Glial cell line-derived neurotrophic factor (GDNF) immunoreactivity has been found in neurons of the dorsal motor nucleus of vagus in humans (Del Fiacco et al., 2002). Aminopeptidase A and angiotensin receptors have also been detected here (Zhuo et al., 1998; De Mota et al., 2008). Connections between the dorsal motor nucleus of vagus and the solitary nucleus have been shown in fetal human specimens, as in other non-human primates (Zec and Kinney, 2003).

### Solitary Nucleus

The solitary tract (sol) is a heavily myelinated fiber bundle that extends from the level of the facial nucleus

up to the spinal cord. A large region of the dorsal tegmentum, mostly medial to the tract, is the solitary nucleus. Early studies of the solitary tract in humans and experimental mammals have established that the tract is composed of fibers from the trigeminal and facial nerves rostrally (Nageotte, 1906), the glossopharyngeal nerve in the intermediate region and the vagus nerve caudally (Bruce, 1898; Papez, 1929; Pearson, 1947).

Evidence from studies in experimental animals revealed the solitary nucleus (Sol) as the initial relay for baroreceptor, cardiac, pulmonary chemoreceptor, and other vagal and glossopharyngeal afferents (see Loewy, 1990). For example, the Sol in the rat is known to contain neurons activated by baroreflex afferents, while Sol projections to the ventrolateral part of the caudal rhombomeres are essential for baroreflex-induced sympathoinhibition and cardiovascular stimulation (Guyenet et al., 1989). Visceral signals transmit via branches of the facial, glossopharyngeal, and vagal nerves which terminate viscerotopically across special (gustatory) and general visceral afferent divisions of the primate solitary nucleus (Norgren, 1990).

Chemoarchitectonic analysis (Benarroch et al. 1995) revealed important topographic relationships between catecholamine and nitric-oxide-synthesizing neurons, including innervation of intrinsic blood vessels (both tyrosine hydroxylase- and NADPH-diaphorase-reactive processes innervate intrinsic blood vessels in the Sol). Such a topographic relationship may be associated with regulation of autonomic reflexes, sympathetic excitatory drive, and intrinsic control of cerebral blood flow in humans (Benarroch et al., 1995). Human Sol fiber trajectories form three major bundles: through the intermediate reticular zone, across the dorsomedial reticular formation toward the dorsal raphe, and a ventral one toward the gigantocellular reticular nucleus (Gi) (Figures 8.12–8.34). The terminals were shown within the Sol, dorsomotor nucleus of vagus, and reticular formation (Ruggiero et al., 2000). Using chemoarchitecture, Törk et al. (1990), then McRitchie and Törk (1993, 1994) comprehensively delineated the human Sol. The lowest AChE reactivity was displayed by the ventrolateral, ventral, and intermediate nuclei of Sol. Slightly more reactivity was displayed by the dorsal, dorsolateral, and commissural nuclei. Intense reactivity was displayed by the gelatinous medial nuclei. Extremely intense reactivity was displayed by the subsolitary and interstitial nuclei.

Connections of the human solitary nucleus (Sol) have been shown in human fetal brainstem using DiI injection to the caudal raphe at the junction of the nucleus raphe pallidus and the arcuate nucleus. Also connected to the solitary are caudal hindbrain areas related to autonomic

and respiratory control including the dorsal motor nucleus of vagus, nucleus ambiguus complex/ventral respiratory group, rostroventrolateral reticular nucleus (RVL), caudoventrolateral reticular nucleus (CVL), and the caudal hindbrain reticular formation. This connection pattern is consistent with results of other studies on adult experimental animals (Zec and Kinney, 2003). Ruggiero et al. (2000) identified connections between the Sol and areas of the lateral reticular formation and raphe corresponding to cardiorespiratory centers in other species. Baroreceptor reflex failure (Biaggioni et al., 1994), and pediatric respiratory, circulatory, and sleep problems (Becker and Zhang, 1996) have been linked to the Sol in humans.

Parathyroid hormone receptor 2 (Bago et al., 2009), nicotinic acetylcholine (Duncan et al., 2008), somatostatin (Carpentier et al., 1997), and angiotensin II type 1 (Benarroch and Schmeichel, 1998; Zhuo et al., 1998) receptors have been found in the human Sol. Met-enkephalin (Covenas et al., 2004), adrenomedullin (Macchi et al., 2006), serotonin (Paterson et al., 2009), bombesin (Lynn et al., 1996), glial cell line-derived neurotrophic factor (GDNF) (Del Fiacco et al., 2002), and tyrosine hydroxylase (Arango et al., 1988, Saper et al., 1991) immunoreactive cell bodies, and neurokinin immunoreactive fibers (Covenas et al., 2003) are also found here.

The paracommissural nucleus (SolPa) is the most caudal representative of Sol (Figures 8.12–8.18). It appears at the level of the pyramidal decussation and ends with the advent of the gelatinous nucleus. The nucleus is conspicuous by its extremely rich AChE reactivity.

The interstitial nucleus (SolI) commences just caudal to the obex and persists until the accessory trigeminal nucleus, caudal to the main mass of motor trigeminal nucleus; thus, it is the longest and the most rostral representative of Sol (Figures 8.18–8.34). It is closely associated with the solitary tract, at times enveloping it and at times being enveloped by it. The SolI expands at its rostral pole. It is at these levels in the monkey and human that the nucleus has a gustatory function. Possible gustatory function more posteriorly is suggested by the contributions of the ninth and tenth nerves, but has not yet been confirmed. Pritchard, in Chapter 33, provides a comprehensive review of the gustatory role of SolI.

Paxinos and Huang (1995) had recognized a nucleus they called the subsolitary at the rostroventral border of the interstitial solitary nucleus, by its extremely strong AChE reactivity. Paxinos and Watson (2007), in the rat, have renamed this area the trigeminisolitary nucleus because it is the annectant area.

Paxinos and Huang (1995) using AChE staining failed to identify the central subnucleus of the Sol in the

human despite the prominent appearance of this structure in the rat brainstem. The human homolog of the central subnucleus was nevertheless identified on the basis of strong NADPH-diaphorase reactivity by Gai and Blessing (1996).

The commissural nucleus (SolC) lies ventromedial to the paracommissural nucleus and at its caudal end crosses the midline just dorsal to the central canal (Figures 8.12–8.17). The SolC is composed of very small cells that tend to be mediolaterally oriented.

The gelatinous nucleus (SolG) appears in the lateral part of the solitary complex deep to the area postrema (Figures 8.16–8.24). It contains extremely small cells that are spindle-shaped and possess dendrites that are confined within the nucleus. Most cells are tyrosine hydroxylase positive, but are not pigmented and have been shown to be adrenergic (PNMT positive) (Kitahama et al., 1985). The subnucleus is devoid of bombesin staining (Lynn et al., 1996).

The dorsolateral nucleus (SolDL) displays fairly pale and patchy AChE reactivity (Figures 8.17–8.25). It contains small and medium-sized cells arranged in clusters, as well as large, darkly stained cells that are pigmented and tyrosine-hydroxylase-positive. The dorsolateral nucleus occupies the middle third of Sol rostral to the level of the obex.

The dorsal nucleus is the rostral continuation of the dorsolateral nucleus but is distinguishable by its stronger and homogeneous AChE reactivity (SolD; Figures 8.23–8.25). Cytoarchitecturally it is heterogeneous, containing small and large cells. Clusters of bombesin-positive neurons were reported in the dorsal and ventrolateral subnuclei of the human Sol (Lynn et al., 1996). Bombesin coexists with catecholamines in neurons in the dorsal subnucleus, a topographic association that may be relevant to the cardiovascular effects of bombesin.

The medial nucleus (SolM) (Figures 8.14–8.28) is the strongly AChE-reactive region located between the dorsal, dorsolateral, ventral, and gelatinous nuclei. It is composed mainly of very small cells, although a few larger pigmented cells are also visible. The medial nucleus replaces the commissural nucleus rostrally (Figure 8.14) and becomes a rectilinear shape as it occupies the full dorsolateral extent of Sol bordering 10N medially (Figures 8.19–8.28). Further rostrally, it separates 10N from the interstitial nucleus of Sol. The medial nucleus disappears with the loss of 10N (Figure 8.29). A chemoarchitectonic study reported strong bombesin fiber/terminal staining in the medial subnucleus of Sol over its full rostrocaudal extent in both rat and human (Lynn et al., 1996). Another study found the dopamine D2 and D4 receptors to be almost exclusively concentrated in the intermediate and medial subnuclei of Sol (Hyde et al., 1996).



The parasolitary nucleus (PSol) is a conspicuous, AChE-negative, banana-shaped nucleus (with a lateral concavity) featuring small, densely packed cells at the lateral border of Sol. It commences at about the level of the obex caudally and persists until the rostral third of the hypoglossal nucleus (Figures 8.18–8.22).

Cheng et al. (2006) investigated the prenatal development of the cyto- and chemoarchitecture of the human Sol from 9 to 35 weeks, using Nissl staining and calbindin, calretinin, tyrosine hydroxylase, and GAP-43 immunohistochemistry. They observed that the Sol started to show different subnuclei as early as 13 weeks and approached cytoarchitectural maturation from 21 to 25 weeks. Calbindin-immunoreactive neurons first appeared in the medial gastrointestinal area and tyrosine-hydroxylase-immunoreactive neurons in the medial subdivisions of the Sol, starting from week 13. Strong GAP-43 immunoreactivity was also present in the Sol at week 13, while a significant decline was observed at week 21.

### Parabrachial Nuclei

The parabrachial nuclei (PB) are pivotal structures in autonomic control because they perform as an interface between the medullary reflex control mechanisms and the forebrain behavior and integrative regulation of central autonomic systems. While 13 distinct subnuclei have been identified in the rat PB (Fulwiler and Saper, 1984; Herbert et al., 1990), only five have been discovered thus far in primates (Paxinos et al., 2009). Relative to the rat, the human PB are cell poor and it is not obvious that there are human homologs to the numerous subdivisions described in the rat. Fortunately for the study of homologies, most of the PB subnuclei are chemically specified and project via somewhat distinct chemically coded lines to their terminations in the hypothalamus and medial part of the ventrobasal complex of the thalamus (see Chapter 19). The chemically coded afferent projections to the PB are also instructive in establishing subnuclei or homologies and their projections in the human. For example, consider the known catecholaminergic, cholecystokinin-, galanin-, and corticotropin-releasing hormone immunoreactive projections from Sol to the PB in the rat (Herbert and Saper, 1990; Phillips et al., 2001). Somatostatin receptors are also found in PB (Carpentier et al., 1996a, 1996b).

The central part of the human lateral PB contains AChE reactivity, while the dorsal part of the lateral PB is poorly stained for the enzyme. The external part of the lateral PB is also AChE-positive and probably corresponds to the pigmented nucleus mentioned by Ohm and Braak (1987). The human homolog of the most medial part of the medial PB has also been identified by AChE staining.

The medial parabrachial (MPB) nucleus begins more caudally than the lateral parabrachial and is well displayed at the compact locus coeruleus pars alpha (Figures 8.17–8.48). The intensity of AChE staining varies between cell groups, but sometimes also between species; thus, unlike the rat, the human MPB is strongly AChE-positive, especially in its juxtabrachial portion. It is limited rostroventrally by the central tegmental tract before the rostral end of the lateral parabrachial nucleus. The medial part of MPB directly overlies the ventromedial aspect of the superior cerebellar peduncle and is strongly reactive for AChE. The external part of MPB is distinguished by lower AChE reactivity than its medial part.

The lateral parabrachial nucleus (LPB) attains its full extent at the caudal pole of the dorsal tegmental nucleus (Figures 8.39–8.49). The AChE-positive central part of LPB succeeds the pedunculotegmental nucleus caudally, which is distinguished by stronger AChE reactivity. The dorsal part of LPB is, in contrast, poorly stained for AChE. The external part of LPB is AChE-positive. A quantitative autoradiographic study of human fetuses revealed a sharp decrease in the density of somatostatin-binding sites on late stages of gestation (Carpentier et al., 1997).

Gioia et al. (2000) investigated the cytoarchitecture of adult human PB using Nissl and Golgi stains. They observed that the PB is composed of small to medium-sized, round, oval, elongated or polygonal-shaped neurons. The cells were larger on the medial PB when compared to the lateral part. Fusiform neurons had two primary dendrites with occasional small spines. Primary dendrites of multipolar neurons had scant secondary dendritic ramifications. In the medial PB, the multipolar and fusiform neurons showed thinner primary dendrites and wider secondary dendritic arborizations when compared to the lateral parabrachial nucleus. Another study in humans (Lavezzi et al., 2004) showed that the medial PB contained oval and polygonal neurons were usually larger than the lateral PB neurons, with darker and more evident cytoplasm.

Calcitonin gene-related peptide (a neuromodulator in efferent projections from PB to the thalamus and amygdala in rats) was employed as a marker for ascending visceral sensory pathways in the human brain (de Lacalle and Saper, 2000). As well as in establishing affiliations of the human PB, chemoarchitecture of MPB and LPB may be of value in pathological investigation. Carpentier et al. (1998) found that the density of somatostatin-binding sites was significantly elevated in MPB and LPB in the sudden infant death syndrome. Calcitonin gene-related peptide (de Lacalle and Saper, 2000), glial cell line-derived neurotrophic factor (GDNF) (Del Fiacco et al., 2002, Quartu et al., 2007), neurokinin (Covenas et al., 2003) and tyrosine-



hydroxylase (Ikemoto et al., 1998) immunoreactive neurons, and parathyroid hormone (Bago et al., 2009), angiotensin II type 1 (Benarroch et al., 1998; Zhuo et al., 1998) and somatostatin (Carpentier et al., 1997) receptors have been observed in the human PB.

In the human, Kölliker-Fuse nucleus (KF) extends from the caudal pole of the parabrachial nuclei in the rostral hindbrain to the lower portion of the mesencephalon. Lavezzi et al. (2004) examined the human KF in newborns and infants, and described the KF as a group of large neurons, ventrally located to the lateral parabrachial nucleus between the medial limit of the superior cerebellar peduncle and the medial lemniscus. The KF neurons were noticeably larger than those of the parabrachial nuclei. On the basis of the neuronal arrangement, Lavezzi et al. (2004) define two KF subnuclei: the subnucleus compactus which consists of a cluster of a few neurons and has an indistinct outline, and the subnucleus dissipatus adjacent to the subnucleus compactus.

In the rat, KF was proposed to harbor the most lateral cluster of the A7 noradrenergic group (Paxinos and Watson, 1998). We note, however, that KF does not form a well-circumscribed group in the rat, whereas in the cat, KF has been placed everywhere in the region between the superior cerebellar peduncle, the lateral lemniscus, and the motor trigeminal (see discussion by Berman, 1968). Paxinos and Huang (1995) depicted the location of the nucleus in the human brainstem (Figures 8.40–8.45).

Fix (1980) identified a melanin-containing nucleus associated with the superior cerebellar peduncle. He labeled the nucleus "X", using inverted commas presumably to indicate that he did not wish this to be retained as its name. Ohm and Braak (1987) identified the same nucleus and called it the subpeduncular nucleus. This term can be easily confused with the subpeduncular tegmental nucleus (Paxinos and Watson, 1998); for this reason, Paxinos and Huang (1995) used the term subpeduncular pigmented nucleus, as did Ohm and Braak in the title of their abstract. The subpeduncular pigmented nucleus (SPP) is unmistakably AchE-positive in neuropil and cell bodies. It has relatively large, tightly clustered, neuromelanin-containing cells presenting a globular profile in coronal section. Because SPP is attached to the ventrolateral edge of the superior cerebellar peduncle, reaching the lateral lemniscus at the surface, it has cell-poor and fibrous regions surrounding it. Caudally, it commences before the lateral parabrachial nucleus as a group of mainly non-pigmented cells ventral to the superior cerebellar peduncle. More rostrally, it is very favorably displayed and appears as a globular nucleus at the ventrolateral edge of the superior cerebellar peduncle with the majority of its cells pigmented. Further rostrally, it drifts dorsally and intrudes into

LPB, tapering off as a row of cells on the dorsal part of PB. At this most rostral level, only a few pigmented cells are seen, but the characteristic AchE reactivity is present. The cells of SPP are polygonal with no specific orientation. Ohm and Braak (1987) observed neurofibrillary tangles on this nucleus in brains from Alzheimer disease patients. Incidentally, considering their pivotal role within central autonomic regulatory systems, the nuclei of the caudal hindbrain parabrachial region (MPB, LPB, SPP) together with the intermediate zone of the reticular formation (IRt) are thought to be targets of the Alzheimer disease-related pathology (Rub et al., 2001). In another study, Ohm and Braak (1988) described three basic neuronal types in SPP: neuromelanin-containing type I nerve cells, type II cells with lipofuscin deposits, and type III neurons devoid of any pigmentation. The SPP is not the homolog of the KF or of any other known nucleus in experimental animals.

### Periaqueductal Gray

The periaqueductal gray (PAG) is an important central relay in cardiovascular and other autonomic control and modulation of pain. There is also substantial evidence for human homologies to the PAG subdivisions established in rat and cat (Beitz, 1985; Bandler et al., 1991; see also Chapter 10). Thus, Paxinos and Huang (1995) identified dorsomedial, dorsolateral, lateral, and ventrolateral PAG columns in the human (Figures 8.51–8.64). Another chemoarchitectonic investigation based on NADPH-diaphorase reactivity (Carrive and Paxinos, 1994) recognized the supraoculomotor cap in the human PAG. The posterior part of this cap was subsequently distinguished by AchE staining (Paxinos and Huang, 1995). Paxinos and Huang (1995) also outlined the human *pleoglial* PAG – a median structure above the rostral levels of the aqueduct. Like the parabrachial nucleus, the PAG forms an interface between the forebrain emotional system and autonomic centers. It receives afferents from the hypothalamus and amygdala and in turn projects to the intermediate reticular zone. Carrive et al. (1989) showed that the PAG autonomic control is compartmentally organized into PAG columns and coupled to defensive behavior in the rat. Paxinos and Huang (1995) showed a columnar arrangement for the human PAG, which is discussed in detail by Carrive (in Chapter 10).

A somatosensory homonculus has also been suggested in the human PAG by Bittar et al. (2005), with the lower limbs represented rostrally and the head caudally, and the trunk and upper limbs occupying an intermediate position. This somatosensory representation is contralateral, except for the forehead and scalp.

In the human PAG, receptors for parathyroid hormone 2 (Bago et al., 2009), GABA-B (Serrats et al., 2003) and angiotensin II type 1 (Benarroch and

Schmeichel, 1998) have been found. There are also neuropeptide Y (Covenas et al., 2003), bombesin (Lynn et al., 1996) tyrosine hydroxylase (Counhian et al., 1998), met-enkephalin (Covenas et al., 2004) and tyrosine hydroxylase (Benarroch et al., 2009) immunoreactive cell bodies, and substance P, pituitary adenylate-cyclase-activating peptide (PACAP) and vasoactive intestinal polypeptide (VIP) (Tajti et al., 2001) containing fibers.

The nucleus of Darkschewitch (Dk) is found in the periaqueductal gray, dorsomedial to the interstitial nucleus of the medial longitudinal fasciculus at a level posterior to the ascending fasciculus retroflexus. It is non-distinct in AChE preparations.

## RETICULAR FORMATION

The keystone to the organizational plan of the reticular formation in rhombomeres 4–11 offered in this chapter is the intermediate reticular zone (IRt).

### Intermediate Reticular Zone

#### *Historical Considerations*

In 1986 the intermediate reticular nucleus of the rat was recognized as the zone between the gigantocellular and parvocellular reticular nuclei which contains large, medium, and small cells and is slightly more reactive for AChE than its neighbors (Paxinos and Watson, 1998). Presumably, this zone brackets the line separating the alar and basal plate derivatives in development. The line extends radially from the sulcus limitans in the floor of the fourth ventricle to the periphery of the brainstem where the vagal and glossopharyngeal rootlets emerge. Due to its cytoarchitecture and position, the zone was named the intermediate reticular nucleus. Allien et al. (1988) found a distinct punctuated distribution of angiotensin II receptors over cell bodies in what they proposed to be the human homolog of the rat intermediate reticular nucleus (see also Allien et al., 1991). Halliday and colleagues (1988b, 1988c), and later Huang and colleagues (1992), showed tyrosine hydroxylase, and neuropeptide Y (NPY) cell bodies and fibers in what in fact is the intermediate reticular nucleus.

Based on the evidence for the existence of the intermediate reticular zone in humans and, following mappings of tyrosine hydroxylase, serotonin, NPY, and substance P in this area, Paxinos and Huang (1995) proposed an extension of IRt boundaries. Given the heterogeneity of this area (see below), they changed its name from “intermediate reticular nucleus” to “intermediate reticular zone” (IRt). The hallmark of the cytoarchitecture of the intermediate reticular zone is

the polarity of cell bodies and their major dendrites. These cells are oriented along the dorsomedial to ventrolateral axis, mirroring the shape of the zone in coronal sections. This orientation predilection distinguishes the IRt from the adjacent gigantocellular and parvocellular reticular nuclei that contain neurons with various orientations.

#### *Position*

Caudally, the IRt separates the dorsal from the ventral reticular nuclei; rostrally, the IRt separates the gigantocellular from the parvocellular reticular nuclei (Figures 8.5–8.33). The zone commences at the pyramidal decussation and extends to the facial nucleus. It is a convex arc with the convexity facing laterally in the rat but medially in the human (probably due to the enormity of the human inferior olive). Dorsally, outlying tyrosine-hydroxylase-positive cells of this zone are found in the cell-poor region that caps the medial pole of the dorsal motor nucleus of vagus. Laterally, it has a variable extent. At caudal levels, IRt reaches the lateral surface of the caudal hindbrain dorsal to the lateral reticular nucleus (LRt) (Figures 8.14–8.17). Somewhat rostrally, IRt bisects the LRt in its surge to the lateral surface (Figures 8.23, 8.24). Further rostrally, it forms a slab dorsal to the lateral paragigantocellular nucleus and together they reach the lateral surface (Figure 8.30). Caudally, it harbors the retroambiguus, ambiguus, and A1 noradrenergic (norepinephrine) cell groups. Rostrally, it harbors the ambiguus nucleus as well as the C1 adrenergic (epinephrine) group.

#### *Catecholamine Cells*

Catecholamine cells are found throughout the IRt but are more prominent in the part ventrolateral to the ambiguus nucleus (A1 and C1). These regions of the IRt have been called the caudoventrolateral (CVL) and rostroventrolateral (RVL) reticular nuclei of the medulla (Arango et al., 1988). This cell group is thought to be involved in control of sympathetic cardiovascular outflow, cardiorespiratory interactions, and reflex control of vasopressin release. For example, a pathology study showed depletion of catecholaminergic tyrosine-hydroxylase-positive neurons in patients with multiple system atrophy with autonomic failure (Benarroch et al., 1998). The full extent of IRt can be clearly seen in Figure 4 of Arango et al. (1988), which depicts tyrosine hydroxylase immunoreactivity in the caudal hindbrain. This observation was later successfully used by Huang et al. (1992) for delimiting IRt on the basis of the distribution of the tyrosine-hydroxylase-immunoreactive cells and fibers. The distribution of AChE-positive cells in the IRt resembles the distribution of the catecholamine-containing cells. The most distinct AChE-positive

neuropil is associated with RVL at levels where the ambiguous nucleus is most prominent. This AChE reactivity in the IRt (RVL) is associated with cell bodies and fibers and it nearly reaches the lateral surface of the brain.

### **Neuropeptide Y**

NPY-reactive neurons are found throughout the rostrocaudal extent of the ventrolateral IRt, particularly at midolivary levels. Expression of NPY mRNA has also been reported in IRt (Pau et al., 1998). Benarroch and Smithson (1997) described tyrosine hydroxylase and NADPH-diaphorase distribution in the IRt. The distribution of NPY immunoreactivity overlaps tyrosine hydroxylase but not NADPH-diaphorase reactivity (Benarroch and Smithson, 1997), suggesting a possibility of further subdivision of human ventrolateral IRt.

### **Serotonin**

Caudally, the lateral part of the IRt contains some serotonin cells intermixed with the catecholamine cells, though differentially concentrated. Many of these cells, particularly serotonin cells, are very close to the surface of the caudal hindbrain. The more rostral regions of IRt contain only occasional serotonin cells. At rostral levels, most serotonin cells are distributed in the lateral paragigantocellular nucleus, immediately medioventral to IRt (Figure 8.30).

Other studies have also shown serotonin cells in the lateral (Paterson and Darnall, 2009) and dorsal (Fonseca et al., 2001) parts of the IRt in humans. At times, some chemically specified cell groups do not respect classical nuclear boundaries and no adjustment of boundaries can be made that can accommodate the new elements without violating other delineation criteria. However, the IRt has consistently appeared as an entity in the work of a number of investigators who have used retrograde or anterograde labels or different chemically specific stains. Having obtained an "after image" from the pattern of distribution of chemically specified elements, it is possible to detect, in Nissl-stained sections, fusiform cell bodies that are oriented in the direction of the axis that joins the dorsal motor nucleus/solitary complex dorsomedially with the AI/CI cell groups ventrolaterally. The existence in the IRt of "independent" nuclei, that do not share IRt properties, prompted us to reclassify this region from a nucleus to a zone.

### **Substance P**

Substance P is differentially distributed in the caudal hindbrain reticular nuclei. IRt displays more substance-P-positive fibers than adjacent nuclei. The distribution of substance P fibers in IRt is non-

homogeneous. Rostrally, IRt displays a band of substance-P-positive fibers and cells near its border with the parvicellular reticular nucleus. The ambiguous nucleus is the most substance-P-poor region of the IRt. Caudally, the IRt contains a few substance-P-positive cell bodies that are larger than the substance-P-positive cells in the parvicellular reticular nucleus. All substance P cells in the IRt also contain adrenaline (epinephrine) or noradrenaline (norepinephrine). However, most (about 95%) of the catecholamine cells do not contain substance P (Halliday et al., 1988a). Ni and Miller Jonakait (1988) have shown that substance P fibers excellently delineate IRt in the developing mouse.

### **Salmon Calcitonin-Binding Sites**

The IRt can also be delineated by the salmon calcitonin-binding sites (Sexton et al., 1994). It is important to mention, though, that these sites invade some regions of the parvicellular reticular nucleus and the gigantocellular nucleus. IRt neurons have also been shown to contain nicotinic acetylcholine receptors in humans (Duncan et al., 2008).

### **Connections**

There is evidence that cells contained in the IRt have both ascending and descending connections. For example, following small HRP injections into the parabrachial region in cats, King (1980) found separate sheets or layers of retrogradely labeled cells in "lateral tegmental field" (Berman, 1968) that ran parallel to the long axis of the lower brainstem and radially with respect to the ventricle. The more medial gamma and delta layers of labeled cells of King's (1980) description appear to occupy the medial region of the lateral tegmental fields (or parvicellular reticular formation (PCRt in our terminology)) that we have now incorporated into the IRt. Similarly, HRP injection into the caudal vagosolitary complex produced a comparable sheet of labeled cells extending the length of the cat's medulla in what Mehler (1983) also then called the medial part of the PCRt but which we now consider part of the IRt zone. Interestingly, anterograde tracer injection experiments involving IRt in the rat produce confirmatory evidence of ascending projections to the parabrachial region and descending projections to the solitary nucleus and the phrenic motoneuron pools at C4 (Yamada et al., 1988).

In the monkey, injections of HRP into the cervical vagus nerve result in heavy retrograde labeling of neurons in the ipsilateral dorsal motor nucleus of vagus and in the ambiguous nucleus. "Additionally, a few neurons are labeled in the intermediate zone between these two nuclei" (Gwyn et al., 1985), i.e., in the IRt.

### Retroambiguus and Ambiguous Nuclei

The RAmb commences below the pyramidal decussation as a scatter of AChE-positive cells embedded in the part of the IRt that is separated from the rest by the decussating corticospinal fibers. It succeeded rostrally (Figure 8.10) by the ambiguous nucleus loose part (AmbL) which we define according to its position relative to the rat, where it has been identified properly. In turn, the loose part is succeeded by the ambiguous nucleus, semicompart part (AmbSc). After all parts of the inferior olive have fully formed, AmbSc gives way to ambiguous nucleus compact part (AmbC). At the point of hand-over, there is a sudden dorsomedial rise in the ambiguous column (Figure 8.24). RAmb is characterized by diffuse spindle-shaped cells. Amb, by contrast, has large multipolar neurons that stain densely for AChE and display large Nissl granules. At area postrema levels the Amb is represented by only a few cells (Figures 8.17–8.19). At the level of the caudal pole of the dorsal accessory olive, it expands ventrolaterally to conform to the arcuate shape of the IRt (Figures 8.20, 8.21). It becomes a round cluster near the level of the rostral pole of the hypoglossal nucleus and attains maximal size near the level of the roots of the glossopharyngeal nerve (Figure 8.22). At this level, the AChE reactivity associated with the Amb engulfs the surrounding cell-poor zone.

Unlike other regions of IRt, RAmb and Amb do not possess catecholamine or NPY cells and are not invaded by catecholamine- or NPY-containing processes. On the other hand, the human adult Amb contains serotonin-immunoreactive fibers (Halliday et al., 1990) and the human fetal Amb contains high concentrations of somatostatin receptors (Carpentier et al., 1996a, 1996b). In addition, monoamine oxidase A, substance P, and receptors for angiotensin II are scarcest in the RAmb and Amb regions of the IRt (Paxinos et al., 1990). Neurokinin-immunoreactive fibers have also been shown in Amb of humans (Covenas et al., 2003).

The mode of integration of the ambiguous column with the remainder of IRt is still unclear. A case description provided insight into the role of Amb, Sol, and neighboring caudal hindbrain reticular formation as well as the vagal dorsal motor nucleus in central control of swallowing. Thus, lateral medullary syndrome presented with numerous symptoms, including dysphagia, is associated with lesions in the upper caudal hindbrain (Martino et al., 2001).

The rostroventral respiratory group (RVRG) has been placed under the semicompart ambiguous (AmbSC) in the rat. We have likewise placed it in the human by position without other evidence. Pre-Botzinger (PrBo) and Botzinger (Bo) complexes have been placed under the compact ambiguous in experimental

animals, and likewise we have placed it in the human by position.

### Ventral, Medial, and Dorsal Reticular Nuclei

Considering that the existence of the IRt is accepted, the remainder of the reticular formation of the caudal hindbrain can be subdivided in a scheme that is in harmony with the distribution of neuroactive compounds in this area.

The area dorsal and ventral to the IRt (previously known as medullary reticular nucleus) features two distinct nuclei. We call these the medullary reticular nucleus, ventral part (MdV) and the medullary reticular nucleus, dorsal part (MdD), in consistency with the same areas in experimental animals. These were previously known as MRt (medial reticular nucleus of the medulla) and VRt (VRt ventral reticular nucleus; Paxinos and Huang, 1995). The area ventromedial to IRt is the MdV and area dorsolateral to IRt is the MdD. Both MdV and MdD hand over to Gi and PCRt at the rostral pole of the linear nucleus (Figure 8.21).

The caudal pole of the IRt is found at a ventrolateral position below the retroambiguus nucleus (RAmb). Rostrally, it is displaced medially and dorsally by the advancing linear nucleus (Li), which in turn is displaced medially and dorsally by the lateral paragigantocellular nucleus (LPGi) (Figure 8.21). All these nuclei border the inferior olive principal nucleus (IOPr) ventrally and the IRt dorsally.

The MdD contains large catecholaminergic neurons distinguishable by strong tyrosine hydroxylase immunoreactivity and contains smaller cells and fewer substance P fibers than medullary reticular nucleus, ventral part (MdV) (Figures 8.4–8.20).

Studies in experimental animals have shown that the MdD neurons are activated only or mainly by noxious stimulation (Villanueva et al., 1988) and are immunoreactive for several amino acids, opioid, and non-opioid neuropeptides and monoamines including glutamate, GABA, acetylcholine, substance P, catecholamines, and serotonin (Lima et al., 2002). It is thought that MdD serves as a primary pro-nociceptive center in the pain control system that integrates multiple excitatory and inhibitory actions for nociceptive processing (Villanueva et al., 2000; Lima and Almeida, 2002).

### Mesencephalic Reticular Formation

Paxinos and Huang (1995) formerly identified an AChE-positive area in the human adjacent to ctg which was circumscribed but not labeled (Figures 8.62, 8.63). We now identify this area as a homolog of



the retroparafascicular nucleus (RPF) in the mouse, rat, and monkey. Immediately caudal to this area, we see a condensation of cells that we think is a human homolog of the mouse central mesencephalic nucleus (CeMe) identified by Franklin and Paxinos (2008). This is a calbindin-positive cell group and this name was given by topology.

### Lateral Reticular Nucleus

The lateral reticular nucleus (LRt) consists of the lateral reticular nucleus proper, the subtrigeminal division, the linear division, and the parvicellular division.

The LRt proper has AChE-positive neurons in a somewhat dense neuropil that is perforated by negative fibers with longitudinal orientation. It commences caudally at the rostral part of the pyramidal decussation (caudal to Figure 8.12). According to Paxinos et al. (1990), the name “lateral reticular nucleus” is retained only for this part of the nucleus (without qualifiers such as “proper” or “principal”).

The subtrigeminal LRt (LRtS5) features large cells, well stained for AChE, in a dense AChE background. It commences caudal to the principal inferior olive (Figure 8.12). At its rostral pole it becomes fractionated and discontinuous (Figure 8.27). The LRtS5 also contains tyrosine-hydroxylase-positive neurons. The LRtS5 together with MdV and MdD is thought to play a role in autonomic respiratory centers in the caudal hindbrain. In support of this view, Ono et al. (1998) reported severe loss of catecholaminergic (tyrosine-hydroxylase-positive) neurons in LRtS5, MdD, and MdV in patients with myotonic dystrophy who suffered alveolar hypoventilation and respiratory insufficiency.

The LRt extends medially over the caudal pole of the inferior olive. This linear part becomes separated from the main LRt at the caudal pole of the dorsal accessory olive. Paxinos and Huang (1995) named this epiolivary nucleus, but we now find that it is the homolog of the linear nucleus in rodents. Further rostrally, it shifts medially as a compact rectangular group (Figures 8.12–8.27). Paxinos and colleagues (1990) noticed in the baboon a nucleus in a position similar to the linear LRt that displays large retrogradely filled cells following thoracic HRP injections. This spinally projecting nucleus in the baboon cannot be assigned to LRt because it projects to the spinal cord rather than the cerebellum. Therefore, the linear nucleus may not belong to LRt complex, although the two nuclei are nearly identical morphologically (Paxinos et al., 1990). The similarity of the linear nucleus to LRt was also recognized by Braak (1971). We are now convinced that the epiolivary nucleus is homologous with linear nucleus (Fu et al., 2009).

The parvicellular part of LRt (LRtPC) betrays its presence in the rat by the extremely dense AChE reactivity. In the human, AChE reactivity is found in islets near the surface of the lateral caudal hindbrain immediately external to LRt (Figure 8.21). These small compact cells poorly stained for Nissl and associated with this reactivity belong to the homolog of LRtPC. In humans its size is clearly attenuated in comparison with that in the rat. Human LRt contains high densities of neurokinin-immunoreactive fibers (Covenas et al., 2003). For further details on LRt, see Walberg (1952).

### Gigantocellular, Lateral Paragigantocellular, Gigantocellular Ventral Part, Gigantocellular Alpha Part, and Dorsal Paragigantocellular, and Parvicellular Reticular Nuclei

The gigantocellular reticular nucleus (Gi) appears together with Roller’s nucleus (Figure 8.21). It extends to the level of the exiting facial nerve, where it is succeeded by the caudal part of the pontine reticular nucleus (PnC) (Figure 8.32). A study of the cytoarchitectonic development of the human Gi suggested that immature Gi neurons appear by 16 weeks of gestation after migration and that the subsequent differentiation and maturation progresses gradually and monotonously during the latter half of gestation (Yamaguchi et al., 1994).

The present description of the lateral paragigantocellular nucleus (LPGi) is based on the distribution of serotonin cells. LPGi first appears lateral to the rostral pole of the linear nucleus (Figures 8.21, 8.22). LPGi remains at a lateral position and always ventromedial to the IRT. When the dorsal accessory olive disappears, the LPGi expands medially, where it persists until the rostral pole of the principal inferior olive (Figures 8.27, 8.28). Along its entire length, LM features many fusiform serotonin-containing neurons. Beyond the caudal pole of LM, serotonin cells remain in the region but do not penetrate the linear reticular nucleus; rather, they shift dorsally into the IRT and mingle with the tyrosine-hydroxylase-positive cells of this zone. The spread of the LPGi as shown by Nissl staining matches that of the serotonin-positive cell bodies. More than 150 serotonin-positive cells can be seen on each side of a 50- $\mu$ m section of the caudal hindbrain. The serotonin-positive cells are larger in the LPGi ( $27 \pm 4 \mu\text{m}$ ) than in the caudal part of the intermediate reticular zone ( $19 \pm 4 \mu\text{m}$ ) (Halliday et al., 1988a).

Substance P is found in many of the serotonin-containing cells in the LPGi (Halliday et al., 1988b). Zec and Kinney (2001) examined proximal projections of LPGi using a bidirectional lipophilic fluorescent tracer, 1,1'-dioctadecyl-3,3',3'-tetramethylindocarbocyanine perchlorate (DiI), in postmortem human fetuses and reported diffusion of DiI to the arcuate nucleus (Ar),

nucleus raphe obscurus, hilus of the inferior olive, bilateral Gi, and the intermediate reticular zone (IRt), vestibular and cochlear nuclei, cells and fibers at the floor of the fourth ventricle, medial lemniscus, lateral lemniscus, inferior cerebellar peduncle and cerebellar white matter, central tegmental tract, and capsule of the red nucleus.

The LPGi contains the adrenergic cell group C1 and the noradrenergic A1, A2, A4, and A5 cell groups. Studies on experimental animals have shown that activation of serotonergic cells in the LPGi triggers solitary nucleus-mediated cardiac baroreflex inhibition elicited by noxious stimuli (Gau et al., 2009).

The Gi, ventral part (GiV) is an AChE-poor area above the dorsal accessory olive. It borders the LPGi and IRt laterally and the Gi dorsally. Unlike the rat, cat, and monkey, the human GiV does not have giant cells. It is succeeded rostrally by the gigantocellular alpha-part (GiA).

The GiA forms a cap over the raphe magnus (Figures 8.30–8.32). It has small, medium, and large cells, many of which are oriented mediolaterally. It is bordered laterally by the central tegmental tract as the tract approaches the inferior olive. It is characterized by medium AChE reactivity and has AChE-positive cell bodies. In addition, serotonin-positive cells invade the ventral and lateral part of the GiA (see Chapter 32). The dorsal paragigantocellular nucleus (DPGi) is favorably seen in Figure 8.32 as an AChE-poor region. DPGi is located in the dorsomedial part of the rhombomeric tegmentum, lateral to the medial longitudinal fasciculus, ventral to the prepositus hypoglossal nucleus, and dorsal to the gigantocellular reticular nucleus (Figures 8.23–8.32). DPGi contains loosely and irregularly arranged nerve cells, including round, ovoid, triangular small neurons, slender, triangular or multipolar medium-sized, and occasionally large neurons (Büttner-Ennever and Horn, 2004; Rüb et al., 2008).

Descending projections from the GiV pars alpha and LPGi to the spinal cord have been shown in rats, to the intermediolateral and the sacral parasympathetic nucleus, as well as to regions of the intermediate gray, and to laminae 7–9 and 10 throughout the length of the spinal cord. These diffuse projections suggest that Gi is involved in the direct, descending control of a variety of spinal activities (Hermann et al., 2003). Electrophysiological and physiological studies in rats have also shown that the GiV pars alpha and LPGi provide descending control of pelvic floor organs, specifically by inhibition of sexual reflexes (Hubscher and Johnson, 1996; Johnson and Hubscher, 1998).

The juxtaolivary nucleus (JxO) is an AChE-positive cell group dorsal to the rostral inferior olive, first identified in the rat (Paxinos and Watson, 2007). In the human, JxO lies between the lateral extension of LPGi and the olive (Figures 8.25–8.28).

## TEGMENTAL NUCLEI

### Ventral Tegmental Nucleus

In 1884, von Gudden observed that in the rabbit the majority of the fibers of the mammillotegmental tract terminated in a distinct nucleus of the pontine tegmentum that he named after himself, “das Guddensche Ganglion.” This nucleus is now known as the ventral tegmental nucleus (von Gudden, 1884) (VTg) and is a densely packed, conspicuous nucleus in all species studied except the human.

On the basis of chemo- and cytoarchitecture, Paxinos et al. (1990) and, soon after, Huang et al. (1992) delineated VTg in humans as the large, AChE-reactive nucleus that succeeds rostrally the abducens nucleus, after allowing the root of the seventh nerve to interpose itself between the two nuclei. This area is not a rostral extension of the abducens nucleus because both nuclei taper prior to reaching either side of the root of the seventh nerve. The VTg, according to them, is embedded in the lateral aspects of the medial longitudinal fasciculus (mlf), extending both ventrally into the tegmentum and dorsally into the central gray. According to them, the VTg is succeeded rostrally by the alar interstitial nucleus.

In the first edition of the atlas (Paxinos and Huang, 1995), there were errors in VTg and AII. We are concerned that the location where Paxinos et al. (1990) placed it is in rhombomeres further caudally than it is present in experimental animals. Therefore, in the present atlas, we do not recognize a VTg and now call this AChE-positive cell group an extension of the reticulotegmental nucleus the lateral part (RtTgL). We think that VTg should end ventrolateral to PDTg, and AII is now changed to VTg.

### Dorsal Tegmental Nucleus

Caudally, the dorsal tegmental nucleus (DTg) commences at the level of the rostral pole of the reticular tegmental nucleus (Figure 8.38). It was first identified by von Gudden (1889, cited by Berman, 1968). Chemo- and cytoarchitectonic study of the nucleus in the human (Huang et al., 1992) delineated DTg as a circumscribed, compact, small-celled nucleus conspicuous by its relatively poor AChE reactivity, which contrasts sharply with the dense laterodorsal tegmental nucleus (Figures 8.43–8.48). It extends to the caudal pole of the pedunculotegmental nucleus (PTg). The DTg was erroneously considered to be part of the supratrochlear nucleus (dorsal raphe in current nomenclature) by Olszewski and Baxter (1954). The DTg is completely devoid of serotonin cells, and this supports the original classification of von Gudden (1889) that distinguished it from the raphe nuclei.

Glial cell line-derived neurotrophic factor (GDNF) (Del Fiacco et al., 2002, Quartu et al., 2007) and corticotropin-releasing hormone (Austin et al., 1997) immunoreactive neurons have been observed in the human DTg.

### Posterodorsal Tegmental Nucleus

The posterodorsal tegmental nucleus (PDTg) has been identified by Huang et al. (1992) on the basis of chemo- and cytoarchitecture (Figures 8.38–8.41). The nucleus is distinguished by strong AChE reactivity.

### Laterodorsal Tegmental Nucleus

The laterodorsal tegmental nucleus (LDTg) borders the locus coeruleus and the DTg through some of its course (Figures 8.42–8.50). It outdistances the DTg caudally and especially rostrally where its ventral part persists until DTg compact part is fully displayed (Figure 8.43). In humans, as in the rat, the ventral part of the LDTg (LDTgV) consists of AChE-positive cells that extend into the fibrous tegmentum ventral to PAG. The LDTgV mingles rostrally with PDTg. LDTg cells are extremely AChE-positive but are usually concealed by the intense AChE neuropil of the nucleus. Choline acetyltransferase mRNA has also been shown in human LDTg (Kasashima et al., 1998). Substance P immunoreactivity is displayed by nearly all the large cells of the nucleus (Del Fiacco et al., 1984; Nomura et al., 1987).

### Pedunculotegmental Nucleus

The pedunculotegmental nucleus (PTg) is a prominent cholinergic cell group in the rostral hindbrain of the human, monkey, rat, and mouse. Paxinos and Watson (2006) and Puelles et al. (2007) have renamed the pedunclopontine tegmental nucleus the pedunculotegmental nucleus (PTg), because pons is not a subdivision of the brain in the same subordination as the mesencephalon and rhombencephalon. It is not even in the same subordination of isthmus, because it does not engulf the neuroaxis (Puelles et al., 2007).

We reproduce below the argument that Paxinos et al. (2009) have given for renaming the pedunclopontine tegmental nucleus and for harmonizing the rodent and primate literature by establishing homologies:

“In the human and rhesus monkey, the PTg has been described as having a compact cholinergic part (pars compacta) and a diffuse non-cholinergic part (pars dissipata). In rodents, however, Swanson (1992) and Paxinos and Watson (2006) named a non-cholinergic area lateral to PTg as the retrorubral nucleus. The retrorubral nucleus has never been recognized in primates. We suspected that the retrorubral nucleus of the

rodent is, in fact, the homologue of the PTg pars dissipata of primates. We have studied AChE sections of human, monkey and rat brains and have confirmed that the PTg in all three species is strongly AChE positive in cells and neuropil. Furthermore, we found that the area immediately lateral to PTg (the primate pars dissipata and the rodent retrorubral nucleus) in all three species is only lightly stained for AChE. These findings suggest that the primate PTg pars dissipata is the homologue of the rodent retrorubral nucleus and this could warrant a name change in both cases. However, there are dozens of articles in the literature in which the retrorubral fields (A8 dopamine cell group) have been mistakenly named as the ‘retrorubral nucleus.’ To avoid this confusion, we recommend that the retrorubral nucleus be renamed the ‘retroisthmic nucleus’ since it lies immediately caudal to the caudal boundary of the isthmus. The retroisthmic nucleus is therefore defined as an area in rhombomere 1 between the PTg medially, and the lateral lemniscus and its nuclei laterally. Dorsal to it is the microcellular tegmental nucleus of the isthmus, and rostral to it is the caudal (isthmic) pole of the substantia nigra.”

The compact cholinergic part of human PTg contains strongly AChE-positive cells and neuropil and rides the dorsal aspects of the superior cerebellar peduncle (Figures 8.48–8.53). It has cholinergic and substance-P-positive cells (see Chapter 34). Kasashima et al. (1998) have also shown choline acetyltransferase mRNA in human PTg neurons.

In Figure 8.52, directly medial to the spinothalamic tract there is an area of AChE reactivity. Olszewski and Baxter outlined two nuclei in this position: the subcuneiform and the diffuse pedunculotegmental. We believe that their scheme is not entirely correct, but we cannot at present make another proposal. This region is probably transversed by ascending AChE fibers of the PTg. Riley (1943), referring to Ziehen (1934), included this region in “area U”.

### Microcellular Tegmental Nucleus

An extensive parvicellular and AChE-reactive nucleus was identified medial to the parabigeminal nucleus of the rat (Paxinos, 1983, 1985; Paxinos and Butcher, 1986). It was called the microcellular tegmental nucleus (MiTg). No nucleus of such intense AChE reactivity is found medial to the parabigeminal of the human. However, a parvicellular nucleus of low AChE reactivity is found in a position of the human tegmentum analogous to that occupied by the MiTg in the rat. On the basis of these observations, Paxinos et al. (1990) proposed that the MiTg exists in the human but has different AChE properties.

## LOCUS COERULEUS

The locus coeruleus (LC) is a blue-black nucleus consisting of A6 neurons of Dahlström and Fuxe. These

noradrenergic neurons contain neuromelanin. LC is characterized by large AChE-positive cells (Figures 8.37–8.49). Meesen and Olszewski (1949) identified in the rabbit a ventral extension of the LC, which they called LC alpha. This ventral extension included a compact portion and a more extensive diffuse part. In the human, Olszewski and Baxter included the compact portion of the pars alpha in their LC proper and the diffuse part in their subcoeruleus (SubC). Paxinos and Watson (1998) labeled the compact part of the LC that is ventral to PAG (in the fibrous tegmentum) as subcoeruleus alpha (SubCA). However, the cells more closely resemble those of the LC rather than those of the SubC; hence, the term “LC alpha” rather than “SubC alpha” is used in the present description. Unlike LC, which has relatively few spinal-projecting cells, the LC alpha exhibits numerous descending projections to the spinal cord as well as many ascending projections to the forebrain (W R. Mehler, unpublished observations; Satoh et al., 1977). There is strong NPY mRNA expression in the LC (Pau et al., 1998). High concentration of somatostatin-binding sites in the area also indicates presence of somatostatin receptors in the LC (Carpentier et al., 1996a, 1996b). In Alzheimer disease the LC sustains degeneration, but the LC alpha remains unaffected (Marcyniuk et al., 1986a, 1986b). Human LC neurons have been shown to contain glial cell line-derived neurotrophic factor (GDNF) and dopamine-beta hydroxylase immunoreactivity, norepinephrine transporters (Ordway et al., 1997), somatostatin (Carpentier et al., 1997) and angiotensin II type 1 receptors. High densities of corticotropin-releasing hormone immunoreactive axons have also been shown here (Austin et al., 1997).

### Epicoeruleus Nucleus

Unlike the rat, LC of humans confines itself to the ventrolateral corner of PAG and does not cling to the full dorsoventral extent of the mesencephalic tract of the trigeminal (Paxinos et al., 1990). In humans, the space dorsal to the LC and medial to the mesencephalic tract of the trigeminal nerve is occupied by a group of medium cells, which Paxinos and Huang (1990) called the “epicoeruleus nucleus” (EC) (Figures 8.40–8.48). In transverse section this nucleus has the shape of an isosceles triangle, with the base resting on the LC and a small-angle apex pointing dorsally. EC is best seen caudal to the caudal pole of DTg. It remains to be determined whether EC is a separate entity from the medial parabrachial nucleus.

Pathology of major depression was shown to be accompanied by altered norepinephrine transporter (NET) function (a membrane protein responsible for termination of the action of synaptic norepinephrine and a site of action of many antidepressants) in LC

(Klimek et al., 1997). Chemoarchitectonic evidence revealed angiotensin II type 1 receptors in the human LC (Benarroch and Schmeichel, 1998) and somatostatin in the fetal human LC (Carpentier et al., 1996a, 1996b), while the differential decrease in the density of somatostatin-binding sites observed in the fetal LC during development supported the notion that the somatostatinergic systems in LC as well as in LPB may be involved in maturation of the respiratory control (Carpenter et al., 1997). Strong human cocaine- and amphetamine-regulated transcript (CART) mRNA expression was also found in the human LC (Hurd and Fagergren, 2000). The subcoeruleus nucleus is the AChE-positive area dorsolateral to the central tegmental tract (ctg).

## RAPHE NUCLEI

Raphe nuclei are located in the midline, along the rostrocaudal extension of the brainstem in humans (Olszewski and Baxter, 1954). They include the raphe obscurus and raphe magnus nuclei, median and paramedian raphe nuclei, raphe pontis nucleus, and dorsal raphe nucleus, and consist mostly of serotonergic neurons. Studies in experimental animals have shown that raphe nuclei in the isthmus and rostral hindbrain mainly project to the neocortex, striatum, amygdala, hypothalamus, cerebellum, and other brainstem nuclei such as LC. The raphe nuclei of the rostral hindbrain are considered to regulate the sleep–wake cycle, mood, and cognition; those in the caudal hindbrain are related to pain control (Sasaki et al., 2008). Those in the caudal hindbrain mainly project to the spinal cord.

### Raphe Obscurus and Magnus Nuclei

The raphe obscurus (ROb) possesses AChE-positive cells and dendrites which form two paramedian bands at the divided midline medial to the medial longitudinal fasciculus and the predorsal bundle (Figures 8.15–8.30).

Human ROb neurons show immunoreactivity for serotonin (Paterson and Darnall, 2009), substance P (Del Fiacco et al., 1984; Halliday et al., 1988a; Rikard-Bell et al., 1990), galanin (Blessing and Gai, 1997), neurokinin A and B (Covenas et al., 2003), met-enkephalin (Covenas et al., 2004), and nicotinic acetylcholine receptor (Duncan et al., 2008).

The raphe magnus (RMg) caps the medial lemniscus and is most prominent at the rostral pole of the inferior olive (Figures 8.29–8.34). At this level the raphe (the midline) is wide and colonized by two parallel chains of pontine nuclei (paraphalles nucleus). Cells of RMg



tend to be oriented mediolaterally. The RMg neuropil shows medium AChE reactivity and is interrupted by the AChE-negative fibers of the medial lemniscus. About half of the raphe magnus cells are positive for serotonin and it is possible that serotonin cells are also AChE-positive. Approximately 30% of serotonin cells in RMg also contain substance P in humans (Halliday et al., 1988a). In the rat, serotonergic cells in the RMg and adjacent nucleus gigantocellular reticular nucleus are likely involved in modulation of nociceptive transmission, whereas non-serotonergic cells modulate stimulus-evoked arousal or alerting as well as spinal autonomic motor circuits involved in thermoregulation and sexual function (Mason, 2001).

RMg has connections mainly to the periaqueductal gray and the spinal cord, suggesting its involvement in nociception (Hornung, 2004). There are also gender differences in RMg, with females containing more neurons than males, and males showing a higher proportion of large multipolar and fusiform, but not of ovoid neurons (Cordero et al., 2001).

### Median and Paramedian Raphe Nuclei

In the rat, Paxinos and Watson (1998) used the term median raphe (MnR) to describe the midline nucleus containing large cells that are predominantly serotonin-positive. The MnR cells differ from the remaining cells in what was formerly called the central superior medial nucleus (the region between the tectospinal tracts) in terms of morphology, chemoarchitecture, and connectivity. Paxinos and Watson abandoned the term “central superior medial nucleus” because this nucleus actually encompasses two heterogeneous nuclei. Taking Mehler’s suggestion, Paxinos and Watson (1998) introduced the term “paramedian raphe nucleus” (PMR) to refer to the more laterally located non-serotonergic cells, which are distinct from MnR (see their Figures 48–51).

In the human, the distribution of serotonergic cells is much more extensive than that of the rat. However, many (but not all) laterally located serotonin cells of the human morphologically resemble the remainder of the reticular formation cells and do not present a specific dendritic orientation. The serotonin cells of MnR are characterized by their lack of laterally oriented dendrites. In the rat, an intense AChE-positive zone separates MnR from PMR. In humans, a similar AChE-positive zone shepherds the large median raphe cells rostrally but is invaded by the larger midline cells caudally (Paxinos and Huang, 1995). The shepherding zone, as well as MnR and PMR, display bowed boundaries that collectively give this region the appearance of a barrel with staves.

The MnR is found dorsal and rostral to RTg in the rostral rhombomeres and isthmus (Figures 8.44–8.51). Rostrally, MnR is limited by the decussation of the superior cerebellar peduncle. Dorsal to the decussation, the nucleus merges with the caudal linear nucleus.

Human PMR contains corticotropin-releasing hormone-immunoreactive fibers (Austin et al., 1997). MnR neurons contain GABA-B receptor mRNA, co-localized with serotonin transporter receptors in rats (Serrats et al., 2003). Some MnR neurons contain substance P (Baker et al., 1991b).

### Raphe Pontis Nucleus

Unlike other raphe nuclei, the cells of raphe pontis nucleus (RPn) are not serotonin-positive (Figures 8.32–8.36). McKinley et al. in Chapter 18 observes that in a narrow sense the raphe pontis nucleus is, in fact, the caudal pole of MnR and proposes to abandon the term “raphe pontis nucleus” as referring to a region harboring serotonin neurons. We maintain this cell group and assume it is the homolog of the raphe pontis found in rhombomere 4 in the rat. McKinley et al. describe this cell group in detail in Chapter 18.

### Dorsal Raphe Nucleus

The dorsal raphe nucleus (DR) shows extreme AChE reactivity in the neuropil of its wings (Figures 8.37–8.57). The median strip of cells is associated with less reactivity in the neuropil; consequently the cells, which display medium reactivity can be visualized. An autoradiography study showed that neurons of dorsal raphe are characterized by NPY mRNA expression (Pau et al., 1998). Hurd and Fagergren (2000) reported strong human CART mRNA expression in the DR, though it is not clear whether the message is in serotonin-containing cells.

DR neurons are not only confined to the midline, but extend laterally into the ventral periaqueductal gray and surround the medial longitudinal fasciculus. The caudal part of the dorsal raphe nucleus (DRC) consists of a narrow double string of cells extending caudally up to the level of the abducens nucleus. The rostral end of DR neurons has been shown to have a similar morphology with those of CLi (Hornung, 2003).

Human DR neurons have been shown to contain substance P, with a 40% co-localization with serotonin (Baker et al., 1991b). Serrats et al. (2003) observed GABA-B receptor mRNA containing neurons in human DR; 85% of these also contain serotonin transporter mRNA. A high density of radioligand binding to norepinephrine transporters is also found in DR (Ordway et al., 1997).

## VENTRAL MESENCEPHALIC TEGMENTUM AND SUBSTANTIA NIGRA

Chapter 13 gives a comprehensive pictorial representation of the mesencephalic dopamine groups on the basis of tyrosine hydroxylase immunoreactivity.

### Caudal Linear Nucleus

The caudal linear nucleus (CLi) is more extensive in the human than in the rat (Figures 8.52–8.56). In humans, it extends from the medial longitudinal fasciculus dorsally to the interfascicular nucleus ventrally. Caudally, it rides on the rostral aspect of the decussation of the superior cerebellar peduncle until it joins the rostral tip of MnR. Some CLi cells infiltrate the decussation of the superior cerebellar peduncle to mingle with the median raphe. The caudal linear nucleus consists of a median and two paramedian corridors of cells that are strikingly different in their chemoarchitecture. The median corridor is AchE-negative and contains serotonergic neurons, while the lateral corridors are AchE-positive and contain numerous tyrosine-hydroxylase-positive cells.

Paxinos and Huang (1995) named the unpaired midline corridor featuring the serotonin cells – the azygos part of CLi. This azygos part succeeds MnR (with which it is continuous through cell bridges blasting through the superior cerebellar peduncle). The AchE-positive catecholaminergic corridor is the zygos part of CLi. The paramedian clusters do not extend as far caudally as the median cluster; thus, it is only the median cluster that meets MnR. The CLi borders the rhomboid nucleus and is succeeded rostrally by the rostral linear nucleus at approximately the point of the caudal pole of the red nucleus.

### Interfascicular Nucleus

The interfascicular nucleus (IF) straddles the interpeduncular nucleus. Laterally, the IF is in contact with the paranigral nucleus. In contrast to rats, cats, and monkeys, in which the IF is a median cluster, the human IF is small and consists of two paramedian clusters that are connected only by cell bridges (Halliday and Törk, 1986). Compared to other nuclei of the ventral mesencephalic tegmentum, it has significantly smaller cells (Halliday and Törk, 1986). Both the cells and the neuropil are densely AchE-positive.

### Rostral Linear Nucleus

The rostral linear nucleus (RLi) consists of scattered pigmented AchE-reactive cells within and dorsomedial

to the superior cerebellar peduncle as the peduncle encapsulates the red nucleus (Figures 8.57–8.64).

### Retrobulbar Fields

The dopamine-containing (tyrosine-hydroxylase-positive) retrobulbar fields are found caudal and dorsal to the caudal pole of the red nucleus, at the level where the third nerve forces its way through the red nucleus. In drawing the borders of the human retrobulbar fields it may be useful to consider the map of the pigmented cells in the human brainstem presented by Mai et al. (1997).

### Paranigral Nucleus

In contrast to the rat, the paranigral nucleus (PN) of humans is extremely AchE-reactive and abuts not on the interpeduncular nucleus as in the rat but on the medial pole of the substantia nigra (Figures 8.52–8.55). Del Fiacco et al. (2002) observed many glial cell line-derived neurons in the human substantia nigra, paranigral nucleus, and the region immediately dorsal to it. These regions are considered to belong to the human counterpart of the rodent A10 cell group (Pearson et al., 1990).

### Parabrachial Pigmented Nucleus

The parabrachial pigmented nucleus (PBP) occupies the space between the substantia nigra compact part and the red nucleus (Figures 8.52–8.64). It is characterized by AchE-positive neurons and a neuropil of medium to dense reactivity.

### Substantia Nigra

The substantia nigra (SN) displays intense AchE reactivity in the cell bodies and neuropil of its compact (SNC) and lateral (SNL) parts (Figures 8.52–8.64). In places SNC divides or envelopes the reticular part. The dopamine-containing neurons are AchE-positive but are not cholinergic (Butcher and Talbot, 1978). The reticular part of SN is less reactive than the compact part. Damier et al. (1999a) divided human SN into a calbindin-rich region (matrix) and five calbindin-poor nigral subdivisions (nigrosomes). For a comprehensive description of SN, see Chapter 13.

Substance P (Gibb, 1992), tyrosine hydroxylase (Damier et al., 1999a), and GABA-immunoreactive neurons (Petri et al., 2002; Waldvogel et al., 2004), and tyrosinase mRNA (Xu et al., 1997) have been observed in human SNC. Calbindin-positive neuropil is found throughout the reticular part of SN and most of the SNC (Damier et al., 1999a).

The most striking neuropathologic finding in Parkinson's disease is a progressive loss of dopaminergic neurons in SNC. The loss of dopamine-containing neurons is significantly higher in the nigrosomes when compared to the calbindin-rich matrix (Damier et al., 1999b).

### Interpeduncular Nucleus

The interpeduncular nucleus (IP) displays an AChE-dense zone that straddles a core of medium reactivity (Figures 8.51–8.61). This pattern is not readily comparable to that shown in the rat. IP has been implicated in sleep regulation (Herkenham, 1991), pain sensitivity (Meszaros et al., 1985), and active avoidance behavior (Hammer and Klingberg, 1990). Panigrahy et al. (1998) observed high muscarinic receptor binding in the lateral, high serotonergic binding in the dorsal, and high opioid receptor binding in the medial subdivisions of IP in humans.

As in the rat, the fasciculus retroflexus in humans displays an AChE-dense core surrounded by an AChE-negative area.

## CRANIAL MOTOR NUCLEI

### Hypoglossal Nucleus

The hypoglossal nucleus (12N) is one of the most AChE-reactive nuclei in the staining of both cell bodies and neuropil (Figures 8.14–8.25). Its caudal representative is the ventrolateral division (I2VL). This division possesses large AChE-positive neurons found within the fibrous zone ventrolateral to the central canal, at the medial border of MdV (see above). As in the rat (Krammer et al., 1979), the I2VL disappears as soon as the dorsal division develops. In the rat, the 12VL innervates the geniohyoid muscle (Krammer et al., 1979). The ventromedial division of 12N is the largest, and in the rat it innervates the genio-glossus muscle (Krammer et al., 1979). We are not confident about the homology of the dorsal division because another subnucleus (potentially a laterally displaced dorsal division) appears in the human. In the rat, the dorsal division innervates the styloglossus and hyoglossus muscles. The nucleus of Roller accompanies the rostral third of the hypoglossal nucleus (Figures 8.21–8.25).

### Facial Nucleus

The facial nerve nucleus (7N) abuts the rostral end of IRT and persists until the level of the exiting facial nerve (Figures 8.31–8.34). In humans, as in the rat, the 7N contains AChE-reactive cell bodies and neuropil. Subdivision of the 7N in the human (see Figures 8.31–8.34) (Pearson, 1947; Paxinos and Huang, 1995) is in conflict

with this in the monkey (Satoda et al., 1987). For more information on the nucleus, see also Chapter 9.

The stylohyoid part of the facial nucleus (7SH) is found above the caudal half 7N. It assumes a compact pyramidal shape at its rostral pole immediately medial to the exiting facial nerve (Figure 8.32). The accessory 7N are intensely reactive for AChE. Surrounding the 7N is an AChE-positive zone which was named the perifacial zone in the human and the brain (Paxinos and Huang, 1995).

### Motor Trigeminal Nucleus

The caudal pole of the motor trigeminal nucleus appears medial to the exiting root of the facial nerve (Figure 8.33). It extends rostrally to the dense caudal pole of LC. The motor trigeminal nucleus is strongly active for AChE (cells and neuropil) and the reactivity extends into the cell-poor peritrigeminal zone (Paxinos and Huang, 1995) (Figures 8.36, 8.37).

### Abducens Nucleus

The abducens nucleus (6N) is located ventral and caudal to the horizontal limb of the exiting facial nerve (Figures 8.31–8.33). The 6N consists of large motoneurons and small multipolar interneurons. It has prominent AChE-positive cells but its neuropil is only of medium intensity. The nucleus is also discussed in Chapter 9.

### Trochlear Nucleus

The trochlear nucleus (4N) is found in an invagination of the medial longitudinal fasciculus near the level of the junction of the inferior and superior colliculi (Figures 8.53–8.55). Its motoneurons are AChE-positive but its neuropil is only moderately reactive. The 4N is separated from the rostrally lying oculomotor nucleus by a small cell-free space. The two nuclei can be distinguished by the fact that 4N is embedded in the fasciculus while the oculomotor nucleus is cradled in it.

At the caudal pole of the trochlear nerve the midline between the two medial longitudinal fasciculi features a dense AChE segment (Paxinos et al., 1990). This may correspond to the parvicellular "compact interfascicular nucleus" (CIF) of Olszewski and Baxter (1954).

### Oculomotor Nucleus

Olszewski and Baxter (1954) report that the oculomotor nucleus (3N) is approximately 5 mm long. It extends from the trochlear nucleus to the unpaired anterior portion of the nucleus of Edinger-Westphal (EW) (Figures 8.56–8.58). The caudal pole of the oculomotor nucleus is more reactive for AChE than the trochlear nucleus.

EW is originally described as a cytoarchitecturally defined cell group considered as the location of preganglionic neurons of the ciliary ganglion. However, recent studies suggest that EW has come to indicate different nuclei in different species. It is reactive for AChE in both its cells and neuropil (Figures 8.58, 8.59).

## SOMATOSENSORY SYSTEM

### Gracile Nucleus

At the level of the pyramidal decussation, the tapering caudal pole of the gracile nucleus (Gr) appears as small clusters of AChE-positive cell bodies. Rostrally, the main body of Gr appears with the characteristic patches of AChE reactivity corresponding to clusters of cells separated by AChE-negative myelinated fibers (see Chapter 25). The Gr persists almost to the rostral pole of the area postrema (Figure 8.19).

### Cuneate Nucleus

The cuneate nucleus (Cu) first appears at midlevels of the pyramidal decussation (Figure 8.7) and extends to the rostral pole of the area postrema (Figure 8.21). The Cu displays patches of AChE reactivity similar to those of Gr but of higher intensity. Attached to the borders of some compact bundles of the cuneate fasciculus are clusters of large cells that are well stained for Nissl (density near the brain surface on the border with the gracile nucleus in Figure 8.19). The neuropil of these clusters is extremely reactive for AChE. It seems to correspond to the area reported to contain substance P fibers by Del Fiacco et al. (1984) and Covenas et al. (2003).

### External Cuneate Nucleus

Unlike other species, the human external cuneate nucleus (ECu) occupies a greater area of the medulla than Cu or Gr (Figures 8.13–8.25). It features large cells heavily stained for AChE on a pale background. It expands at the level of the obex and becomes the largest of the dorsal column nuclei rostral to the obex (Figure 8.22). At its rostral pole it narrows and is found between the mediadorsal aspect of the inferior cerebellar peduncle, the spinal vestibular nucleus, and the spinal trigeminal nucleus. It terminates short of the rostral pole of 12N (Figure 8.25).

### Pericuneate, Peritrigeminal, X, and Paratrigeminal Nuclei

#### Medial Pericuneate Nucleus

At the level of the obex, a narrow zone of pale AChE reactivity appears in the neuropil ventral to the dorsal

column nuclei (Figures 8.16–8.24). Paxinos and colleagues (1990) named this zone the “medial pericuneate nucleus.” This basal zone features small, medium, and occasionally large neurons that are AChE-positive. The most medial part of this zone interposes itself between EC, solitary, and interpolar spinal trigeminal nuclei. This medial (basal) pericuneate zone (MPCu) was included in Cu by Olszewski and Baxter (1954), even though it can be seen in their photomicrographs to be separate from Cu proper and possesses smaller cells (their plates 10 and 11). At levels caudal to the obex, cells in MPCu are diffuse and smaller. Rostral to the level of the area postrema (about 1 mm from the obex) these cells increase in number and become more heterogeneous in size and shape. At one point, MPCu cells appear as a triangular mass that merges rostrally with large, rounder cell clusters (Figures 8.17–8.24). A comparable cell cluster is shown by Olszewski and Baxter in their plates 12 and 13, lateral to the solitary nucleus and medial to the spinal trigeminal nucleus. In AChE-stained sections, other small AChE-positive cells extend into the pale neuropil capping the oral pole of Cu (Figure 8.22). This basal MPCu is coextensive in length with 12N. There is no basal region ventral to the gracile nucleus, except for a few clusters at its oral pole.

#### Lateral Pericuneate Nucleus

Lateral and ventrolateral to the external cuneate nucleus there are variably shaped aggregates of chiefly large AChE-positive neurons intercalated in the medial edge of the inferior cerebellar peduncle. The most prominent group of these cells frequently forms a wedge separating the cuneate fasciculus from the dorsal part of Sp5. This chain of cells extends from the level of the obex to the oral pole of ECu (Figure 8.22), equivalent in length to the hypoglossal cell column. This cell group was described by Ziehen (1934) as the “promontorium” (Latin, “to jut out”) and was considered part of the insular nuclei of ECu by Olszewski and Baxter (1954, their plate 10). This nucleus has been confused with nucleus X (described below). Paxinos and colleagues (1990) have called it the “lateral pericuneate nucleus”. Both the lateral pericuneate (LPCu) and medial pericuneate (MPCu) nuclei were identified as separate but related entities by Braak (1971). Braak adopted Ziehen’s (1934) term “promontorium” for the lateral group and coined the term “repagulum cuneati” (Greek, pagus, “something fixed or fastened together”) for the medial group of cells basal to Cu.

#### Peritrigeminal Nucleus

The peritrigeminal nucleus (Pe5) is in places continuous with LPCu and is found lateral, ventral, and medial to Sp5. Caudally, it commences at the level of



the caudal pole of the dorsal accessory olive and extends to the rostral pole of 12N (Figures 8.15, 8.16). Olszewski and Baxter (1954) included the lateral segment of Pe5 in their insula cuneati lateralis (their plate 10). The ventral part of Pe5 is usually found between Sp5 and the subtrigeminal LRt. At times, however, it is found ventral or lateral to the subtrigeminal nucleus. A ventromedial cluster that receives anteroventral quadrant fibers has been labeled the paravagal nucleus by Braak (1971) (small-celled nucleus between the labels Amb and IRt). The Pe5 has a medial extension that intercedes between Sp5 and the LRt.

A distinct ascending neuronal projection from the thermoreactive cells of the peritrigeminal nucleus to the thermoreactive cells of the medial preoptic nucleus has recently been described in rats by Bratincsak et al. (2008).

#### **Afferent Connections of the Pericuneate and Peritrigeminal Nuclei**

In experimental animals, the pericuneate and Pe5 receive ascending anterolateral spinal quadrant fiber connections (via the inferior cerebellar peduncle) and do not receive dorsal root primary fibers (Mehler, 1969). Nucleus X and the paratrigeminal nucleus (Pa5) project to the cerebellum (Mehler, 1977; Somana and Walberg, 1979). The MPCu cells may receive afferents from the same ascending fiber system that projects to LPCu. Cervical dorsal root connections to the pericuneate cells cannot be ruled out. Cortical input to the basal dorsal funicular nuclear region has been verified in humans (Kuypers, 1960); rubrobulbar connections with the region have also been described (Holstege and Tan, 1988). The MPCu cells are believed to have connections with the overlying dorsal column nuclei that function as an intermediate zone (Kuypers and Turek, 1964). Differential studies of retrograde cell labeling, following HRP injections into the ventral posterior lateral thalamic nucleus, demonstrated that many cells in the medial basal pericuneate zone (PCu) that convey tactile information also project to the thalamus through the medial lemniscus with gracile and cuneate axons. However, Ostapoff et al. (1988) have concluded that what might be the homologs of the PCu cells in the racoon relay deep subcutaneous kinesthetic sensations ending chiefly in the ventral intermediate (Vim)-like shell region rostral to the tactile thalamic nucleus. They also confirmed that the caudally situated cells of subgroup X project to the cerebellum, but cells they identified as rostrally situated subgroup X, like nucleus Z, also project to the thalamic shell region.

In animal experiments, cells capping the oral pole of Cu project to the cerebellum and do not join the medial lemniscus (Mehler, 1977). Vestibular group F-like cells (FVe) intercalated in the ventral caudal pole of the spinal

vestibular nucleus (SpVe) give rise to a third vestibulospinal pathway (see review by Mehler and Rubertone, 1986). The ascending spinal fibers that delineate both the lateral X group and the medial basal column nuclei also appear to make connections with group F-like cells at this level of transition between the oral pole of the cuneate nuclei and the caudal pole of the vestibular nuclei.

#### **Nucleus X**

Sadjadpour and Brodal (1968) identified nucleus X as a cell group related to the dorsal boundary of SpVe, extending from the rostral level of Ecu to the caudal level of the dorsal cochlear nucleus. They describe nucleus X as a small triangular area just medial to the inferior cerebellar peduncle, featuring small, lightly stained cells. Paxinos and Watson identified nucleus X in *The Rat Brain in Stereotaxic Coordinates* (Paxinos and Watson, 1998) as the AChE-reactive rostral continuation of Ecu. We observed a similar AChE-reactive cluster of small cells in the position described by Sadjadpour and Brodal. Larger cells invade or form a boundary around nucleus X and these cells may belong to SpVe (Sadjadpour and Brodal, 1968). We believe that the ventral part (between the spinal vestibular nucleus and the inferior cerebellar peduncle) is different from SpVe, but we have not grouped it with nucleus X because of the larger cells of this area and its poorer AChE reactivity. Nucleus X can be confused with the insulae cuneati lateralis of Olszewski and Baxter (our lateral pericuneate nucleus). If we accept Sadjadpour and Brodal's view, nucleus X is unlikely to extend this far ventrally (Figures 8.26, 8.27). In addition, LPCu has large cells whereas nucleus X, according to Sadjadpour and Brodal, has small cells.

#### **Paratrigeminal Nucleus**

In the rat, the paratrigeminal nucleus (Pa5) forms a crescent between the spinocerebellar tract and the spinal tract of the trigeminal, usually invading the latter. The Pa5 of the rat features small cells and is characterized by light AChE and dense substance P reactivity. Some of its cells are substance P positive (Chan-Palay, 1978a, 1978b). While we accept Chan-Palay's definition of this nucleus in the rat, we disagree with her on the human homolog of the Pa5. She considers the insulae cuneati lateralis of Olszewski and Baxter to be the Pa5 of the human. Paxinos and colleagues (1990) have grouped the dorsal insula cuneati lateralis with LPCu and the ventral insula with the peritrigeminal zone. They suggested that the human Pa5 may be, in fact, a string of cells contained primarily within the spinal tract and based their parcellation on the basis that the Pa5 of the rat has small cells in agreement with the parvicellular clusters within the human spinal tract and in contradistinction to the lateral pericuneate zone, which has large cells. An inconsistency in the homology is

that the Ad reactivity of proposed Pa5 of the human is lower than that displayed in the rat.

### Spinal Trigeminal Nucleus

The caudal spinal trigeminal nucleus (Sp5) is characterized by strong AChE reactivity in the superficial layers, including the substantia gelatinosa. The marginal zone of the caudal part of Sp5 can be distinguished because it is less AChE-reactive than the gelatinous nucleus but more than the spinal tract. Some AChE-reactive cells are found totally within the cuneate fasciculus, yet strong AChE reactivity suggests that they most likely belong to the gelatinous part of the caudal Sp5 rather than to the cuneate system. Also, NPY mRNA expression was found within this nucleus (Pau et al., 1998).

The oral Sp5 (Sp5O) has a concentric pattern of AChE reactivity with an extremely AChE dense core (Figures 8.31–8.35). It is succeeded rostrally by the less reactive principal sensory nucleus of the trigeminal nerve. In the principal sensory trigeminal nucleus the AChE reactivity is distributed in small patches adulterated by negative areas. In the principal sensory trigeminal nucleus the AChE reactivity is distributed in small patches adulterated by negative areas. The interpolar nucleus (Sp5I) displays moderate AChE reactivity, although there are occasional extremely intense patches that correspond to parvicellular regions (Figures 8.16–8.30). In the ventral part of the nucleus a rodlike structure appears (circular in cross-section), featuring small compact neurons and extremely AChE-dense neuropil. No such structure appears in the rat. Both Sp5O and Sp5I are reported to contain significant numbers of somatostatin receptors as revealed by somatostatin-binding sites (Carpentier et al., 1996). In humans, Sp5 neurons have been shown to contain serotonin, calcitonin gene-related peptide, and substance P (Smith et al., 2002), bombesin (Lynn et al., 1996), glial cell line-derived neurotrophic factor (GDNF) (Del Fiacco et al., 2002), met-enkephalin (Covenas et al., 2004), neurokinin (Covenas et al., 2003), and parathyroid hormone receptor 2 (PTH2R) (Bago et al., 2009) immunoreactivities.

### Mesencephalic Trigeminal Nucleus

The mesencephalic nucleus of the trigeminal nerve (Me5) features prominent AChE-reactive cells and, as in the rat, its cells and axons form a thin sheet that forms the lateral border of cylindrically shaped periaqueductal gray (PAG) (Figures 8.35–8.61).

### Endolemniscal Nucleus

At caudal medullary levels, long islands of cells strongly reactive for AChE separate dense fascicles of

the medial lemniscus. The islands appear just rostral to the caudal pole of the principal nucleus of the inferior olive. Caudally, they are wholly confined within the medial lemniscus. However, rostrally they unite and flank the lateral side of the medial lemniscus. These cell groups resemble the medial accessory olive but are clearly more medial to it. Given their position, Paxinos et al. (1990) called them the “endolemniscal nucleus.” This nucleus has no equivalent in the rat and not even in the chimpanzee (Paxinos and Huang, unpublished observations).

### B9 and Supralemniscal Nucleus

The B9 is identified as a group of serotonergic cells lying above the medial lemniscus (Figures 8.38–8.48). This cell group also contains a region of extremely strong AChE reactivity that is distinguished as the supralemniscal nucleus (SuL; Figures 8.36–8.46).

## VESTIBULAR NUCLEI

There are four components of the vestibular nuclear complex: the superior, medial, lateral, and inferior (spinal) vestibular nuclei. The vestibular nuclei receive afferents from the labyrinth of the inner ear, from the spinal cord and the reticular formation. Efferents from the vestibular nuclei pass through the inferior cerebellar peduncle to reach the flocculus and nodule, and some form the vestibulospinal projections that descend in the ventral funiculus of the spinal cord.

### Medial Vestibular Nucleus

The medial vestibular nucleus (MVe) succeeds the gracile nucleus rostrally at the level at which the gelatinous solitary nucleus is most prominent and persists rostrally to the level of the abducens nucleus (Figures 8.22–8.33). It has a mottled appearance in AChE. Caudally, embedded in the medial part of MVe, are two clusters of larger cells, the neuropil of which stains strongly for AChE (Figure 8.22). It is important to point out that a group of large neurons positioned ventrally and medially to the main body of MVe is currently considered to be part of the medial rather than lateral vestibular nucleus, as it was previously thought.

### Spinal Vestibular Nucleus

The spinal vestibular nucleus (SpVe) overlaps the rostral pole of the external cuneate and subsequently replaces it (Figures 8.21–8.31). It is rectangular in cross-section and is located dorsolateral to the solitary and spinal trigeminal nuclei. The SpVe is characterized

by the passage of the lateral vestibulospinal tract which, being AchE-negative, contrasts with the medium density of the neuropil of the SpVe. Distribution of somatostatin binding revealed that both MVe and SpVe contain numerous somatostatin receptors (Carpentier et al., 1996). The area above the spinal and dorsal vestibular nucleus is identified as the paravestibular nucleus. Nucleus Y is allocated a real-estate above the inferior cerebellar peduncle prior to ascendance of the peduncle to the cerebellum.

### Lateral Vestibular Nucleus

The lateral vestibular nucleus (LVe) replaces SpVe rostrally (Figures 8.30, 8.31). It displays large AchE-positive cells and has lighter neuropil than the rest of the vestibular nuclei. The superior vestibular nucleus is not optimally displayed in our plates.

### Interstitial Nucleus of the Eighth Nerve

The eighth nerve is AchE-negative but its interstitial nucleus displays AchE-positive cell bodies and neuropil.

### Nucleus of Origin of Vestibular Efferents

The nucleus of origin of vestibular efferents is identified by its proximity to the genu of the seventh nerve by Paxinos and Watson (1998). In the human, as in the rat, the nucleus is distinguished as a group of AchE-positive neurons riding on top of the horizontal limb of the root of the seventh nerve.

## AUDITORY SYSTEM

### Ventral and Dorsal Cochlear Nuclei

Cochlear fibers originating from the spiral ganglion terminate on the ventral and dorsal cochlear nuclei. The ventral cochlear nucleus (VC) displays AchE-positive cell bodies against a light neuropil. It can be distinguished from the pontobulbar nucleus, which is located more medially and which displays high AchE activity in its neuropil. The VC also features a cap that is slightly reactive in the neuropil. The dorsal cochlear nucleus is more reactive in AchE preparations than VC. At the same time the superficial glial zone of the nucleus is less AchE reactive than the nucleus itself.

### Superior Olive

The superior olive is the AchE-poor area rostroventral to the facial nucleus (Figures 8.32, 8.34). The most

conspicuous feature of superior olive in Nissl preparations is the medial superior olive (MSO). It consists of medium-sized, slightly AchE-positive cells and is surrounded by AchE-positive vascular elements that are themselves encircled by an AchE-negative zone. The lateral superior olive is extremely negative in AchE preparation but features some moderately stained capillaries. A conspicuous characteristic of the lateral superior olive is its significantly greater size relative to the size of the entire superior olive nucleus in the rat or the mouse.

The periolivary nuclei surround the superior olive. The dorsal periolivary nucleus (DPO) is the most AchE-reactive structure in the superior olive complex. The position of the dorsal periolivary nucleus is betrayed by MSO, which points directly to it (Figures 8.32–8.34). The dorsal periolivary nucleus probably contains the bulk of the cells that provide the cochlear efferents. The human homologs of the medioventral (MVPO) and lateroventral periolivary nuclei (LVPO) are AchE-positive.

The human homolog of the superior paraolivary nucleus remains an enigma. In the rat, this nucleus is contiguous with MSO. In the human, at this position, we noticed a vertically oriented stream of cells. These cells are medium-sized and AchE-positive, but do not display the dense AchE neuropil that characterizes the dorsal paraolivary nucleus. Judging from the maps of retrogradely labeled cells following HRP injections into the cat cochlea, these cells may also belong to the cholinergic efferent projection.

Our lateroventral periolivary nucleus (LVPO) is the ventral nucleus of the trapezoid body of Kulesza (2008), and our medioventral periolivary nucleus (MVPO) plus nucleus of the trapezoid body (Tz) is the medial nucleus of the trapezoid body. For a comprehensive account of the human auditory system and superior olive, see Chapter 36.

### Trapezoid Nucleus

Identification of the human homolog to the trapezoid nucleus (Tz) has been elusive. Stromberg and Hurwitz (1976) and Richter et al. (1983) suggested tentatively that an attenuated homolog of Tz in the human at the level of the exiting trochlear nerves. Indeed, Paxinos and colleagues (1990) found Tz at the level of the exiting sixth nerve in the shape of a golf club, with most of its cells underlying the central tegmental tract and bordering the medioventral periolivary nucleus. The cells of Tz are large, with weak AchE reactivity, and are found among the caudal crossing fibers of the trapezoid body (Figures 8.33–8.36). It has been pointed out by Paxinos and colleagues (1990) that Tz in the human is much less cellular than in the rat. Met-enkephalin immunoreactive neurons have been shown in the human Tz (Covenas et al., 2004).

### Nuclei of the Lateral Lemniscus

The ventral nucleus of the lateral lemniscus (VLL) succeeds the superior olive rostrally (Figures 8.44–8.46). The VLL can be distinguished from superior olive by its slightly larger cells and by the fact that the cell group, after tapering to an elongated rostral pole, becomes larger and more cellular. In addition, the cells of the VLL are slightly more AChE-reactive than those of superior olive. The VLL commences at the level of the oral pole of the motor nucleus of the trigeminal. The nuclei of the lateral lemniscus reach the caudal pole of the pedunculotegmental nucleus. For a quantification of the human nuclei of the lateral lemniscus, see Ferraro and Minckler (1977).

### Inferior Colliculus

As in the rat (Paxinos and Watson, 1998), the inferior colliculus (IC) of the human displays light AChE reactivity that features slightly denser patches, especially in the external cortex (ECIC) (Figures 8.50–8.56). In the central nucleus of IC, blood vessels are visible as wavy lines of some AChE positivity. For more details regarding IC, see Chapter 36.

### Nucleus of the Brachium of the Inferior Colliculus

The nucleus of the brachium of the inferior colliculus (BIC) shows pale AChE reactivity, but is recognizable because the surrounding dorsolateral tegmentum is AChE-negative (Figures 8.54–8.58). Rostrally, the subbrachial nucleus is found beneath the BIC.

### Medial Geniculate

The medial geniculate (MG) displays weak and blotchy AChE reactivity (Figures 8.56–8.62). By homology with the monkey (Pandya et al., 1994), Paxinos and Huang (1995) recognized the AChE-negative ventral and the AChE-positive medial subnuclei of MG, as well as the strongly AChE-reactive and large-celled suprageniculate nucleus.

## VISUAL SYSTEM

The visual system is covered in detail in Chapter 37, but some elements of the visual pathways represent integral structural parts of the brainstem and as such are presented in this chapter.

### Superior Colliculus

The laminar pattern and the morphology of the major cell types of the superior colliculus closely resemble that found in other species. Laemle (1983) has provided a Golgi analysis of the human superior colliculus (SC). Morphologically, SC can be divided into: (1) a superficial division consisting of the zonal, superficial, and optic layers; (2) an intermediate division consisting of the intermediate gray and white layers; and (3) a deep division consisting of the deep gray and deep white layers (Figures 8.56–8.62).

The AChE reactivity of the human SC resembles that of the rat. The superficial gray layer is the most intensely reactive. The zonal layer is also reactive except for its most superficial strip. The optic nerve layer shows less reactivity than that of the surrounding superficial and intermediate gray layers and is, as a result, conspicuous. The intermediate gray and white layers show intense reactivity. The intermediate white layer displays periodic patches of AChE reactivity as observed in the rat (Paxinos and Watson, 2007). Lattices of high cytochrome oxidase or succinate dehydrogenase activity have been observed in the human SC (Wallace, 1988). The anterior pretectal area is densely reactive for AChE and so is the subadjacent parafascicular nucleus. A number of enigmatic patches of AChE reactivity appear below SC.

### Parabigeminal Nucleus

The parabigeminal nucleus (PBG), while somewhat inconspicuous in Nissl preparations, is all too evident in AChE-stained sections (Figures 8.51–8.54). The human PBG neurons contain choline acetyltransferase (Kasashima et al., 1998) and glial cell line-derived neurotrophic factor (GDNF) (Del Fiocco et al., 2002) immunoreactivity.

### Medial Terminal Nucleus of the Accessory Optic Tract

The existence of the medial terminal nucleus (MT) of the accessory optic tract is ambiguous in humans. On the basis of observations on the monkey, Fredericks et al. (1988) proposed that MT should be present in the human at a position transversed by the lateral rootlets of the oculomotor nerve. We can not find it in humans.

## PRECEREBELLAR NUCLEI AND RED NUCLEUS

Chapter 15 includes a comprehensive description of the cytoarchitecture and connectivity of the precerebellar nuclei.



## Inferior Olive

### **Medial Accessory Olive**

AChE is differentially distributed in the medial accessory olive. The lateral part of the medial accessory olive, the subnucleus A (IOA), displays some of the densest AChE reactivity found in the medulla (Figures 8.14–8.18). Both the neuropil and the cell bodies are densely reactive. IOA is the group that appears at the caudal pole of the olive and, rostrally, greatly outdistances the other nuclei of the medial accessory olive. Subnucleus B (IOB) is slightly less reactive (Figures 8.16–8.18). Subnucleus C (IOC) is less densely stained in the neuropil and the cell bodies are clearly visible. In this respect, it resembles the beta nucleus that it borders (Figures 8.16–8.18).

### **Beta Nucleus**

The beta nucleus (IOBe) in the cat stains poorly for AChE and is confined to the caudal one-third of the olive (Marani et al., 1977). In the monkey, IOBe disappears prior to the full development of the principal nucleus (Brodal and Brodal, 1981). In our human material, IOBe appears as one of the caudal representatives of the olive but vanishes well before the appearance of the rostral division of the dorsal accessory olive (Figures 8.15–8.18).

### **Dorsomedial Cell Column**

The dorsomedial cell column (IODM) is best described as a dorsomedial satellite of IOA in the rostral part of the latter (Figures 8.23–8.27). The IODM is small and usually ovoid; it is depicted in the monkey by Brodal and Brodal (1981; in their figure 1) and in the cat by Marani et al. (1997, in their figure 4A).

### **Ventrolateral Outgrowth**

The ventrolateral outgrowth (IOVL) is actually nuclei “g” and “h” of Olszewski and Baxter (1954) and of Braak (1970). The alternative term is consistent with the nomenclature now commonly used in studies with monkeys (Bowman and Sladek, 1973; Brodal and Brodal, 1981), cats (Marani et al., 1977), and rats (Paxinos and Watson, 2007). The ventrolateral out-growth is serpentine in the transverse plane, with its head (nucleus h) pointing dorsomedially (Figures 8.17, 8.18). It commences slightly more caudally than IODM and ends considerably short of the rostral pole of IODM. It is parallel to the IOA and interposes itself between IOA and IOPr.

### **Cap of Kooy**

The cap of Kooy (IOK) is present at the caudal pole of the olive and represents the most dorsal extension of the complex at that level. It shows moderate AChE reactivity (Figures 8.13–8.18).

### **Dorsal Accessory Olive**

Olszewski and Baxter (1954) and Braak (1970) included in the dorsal accessory olive (IOD) two heterogeneous and discontinuous groups of cells. Paxinos and colleagues (1990) reserved the name IOD for the larger eyebrow-shaped rostral part that caps the dorsomedial aspects of the principal olive. This persists until the frontal pole of the olive, where it has the shape of a comma (Figures 8.15–8.30). The smaller, caudal subnucleus of the IOD (IODC) is rod-shaped (round in cross-section) and, compared with IOD proper, has denser AChE reactivity and features smaller cells. The IODC commences prior to the principal nucleus and continues until the linear nucleus becomes very prominent, at which point it briefly attains a horizontally oriented spindle shape (Figures 8.15–8.18). It is succeeded by the IOD after a small hiatus. Paxinos and colleagues (1990) called the posterior part “caudal dorsal accessory olive.” The inferior olive, including the caudal dorsal accessory olive, was excellently displayed by Kooy (1916). Human IOD contains a high density of met-enkephaline-immunoreactive fibers (Covenas et al., 2004).

### **Principal Inferior Olive**

The inferior olive principal nucleus (IOPr) shows homogeneous medium staining for AChE neuropil and cell bodies (Figures 8.16–8.31). Serotonin (Paterson and Darnall, 2009) and nicotinic acetylcholine (Duncan et al., 2008) receptor immunoreactivities and atrial natriuretic peptide (McKenzie et al., 2001) immunoreactive neurons have been detected in the human IOPr.

### **Conterminal Nucleus**

The conterminal nucleus (Ct) is located on the lateral surface of the amiculum of the olive and displays intense AChE reactivity in cell bodies and neuropil (Figures 8.15–8.26). Filiano et al. (1990) identified that the ventrolateral neurons in the human conterminal nucleus are homologous to the neurons in the cat chemosensitive area described by Truth et al. (1993).

### **Arcuate Nucleus**

The arcuate nucleus (Ar) appears on the anterior surface of the caudal hindbrain, extending dorsally at the midline and partly surrounding the pyramid (Figures 8.19, 8.20). The Ar reacts densely for AChE, as do the pontine nuclei of which it is presumed to be a displaced kin (Olszewski and Baxter, 1954; Mikhail and Ahmed, 1975). Sudden infant death syndrome is associated with high-frequency hypoplasia, characterized by a volume reduction and neuronal depletion of Ar

(Filiano and Kinney, 1992; Matturri et al., 2002). Muscarinic cholinergic (Kinney et al., 1995), kainate (Panigrahy et al., 1997), and serotonergic receptors (Panigrahy et al., 2000) have been found deficient in the Ar of infants with sudden infant death syndrome. Duncan et al. (2008) observed that 5-HT neurons as well as non-5-HT neurons of the human Ar express  $\alpha 4$  nicotinic acetylcholine receptors. This suggests that Ar is a site of interaction where acetylcholine or nicotine influences the central response to carbon dioxide.

Connections between the arcuate nucleus and the caudal raphe (including nucleus raphe pallidus and nucleus raphe obscurus), superficial ventrolateral medullary regions (Zec et al., 1997) and the solitary nucleus (Zec and Kinney, 2003) have been shown in human fetal brainstems.

Angiotensin II type 1 (Benarroch et al., 1998), parathyroid hormone 2 (Bago et al., 2009), and serotonergic receptors (Paterson and Darnall, 2009), and adrenomedullin (Macchi et al., 2006) and glial cell line-derived neurotrophic factor (Quartu et al., 2007) immunoreactive neurons have been observed in the human Ar.

### Paramedian and Dorsal Paramedian Nuclei

Brodal and Gogstad's (1957) paramedian groups correspond to the clusters of AChE-positive cells and neuropil seen within the predorsal bundle at the rostral pole of the hypoglossal nucleus. Olszewski and Baxter's dorsal paramedian groups resemble the pontine nuclei in cytoarchitecture and AChE reactivity. The caudal dorsal paramedian nucleus (CDPMn) is distinguishable from the subjacent 12N, which is extremely AChE-reactive. The CDPMn is most prominent at the rostral pole of the 12N (Figures 8.26–8.29). The CDPMn is succeeded rostrally by its oral companion (ODPMn). Studies in experimental animals suggest that cholinergic input to CDPMn is from the vestibular nuclei or prepositus hypoglossal nucleus (Pr) (Barmack et al., 1992).

CDPMn is located adjacent and medial to the prepositus nucleus in humans. In the mouse (Franklin and Paxinos, 2008), rat (Paxinos and Watson, 2007), and rhesus monkey (Paxinos et al., 2009) atlases, the region in which CDPMn is found is included in prepositus nucleus. This leads to the suggestion that CDPMn is involved in receiving vestibular input and participating in the control of eye movements (Baizer et al., 2007). Calretinin, parvalbumin, nitric oxide synthase, and SMI-32 immunoreactivities have been shown in CDPMn (Baizer et al., 2007).

### Intercalated Nucleus

The intercalated nucleus (In) commences caudal to the obex and persists until the rostral pole of the

hypoglossal nucleus, where it is succeeded by the prepositus hypoglossal nucleus. The intercalated nucleus displays medium AChE reactivity, and some positive cells can be detected through the neuropil. It starts as a narrow wedge between the 12N and the 10N but expands rostrally to fill the vacuum created by the lateral migration of the 10N (Figures 8.14–8.24). Although In is characterized by small cells, at its rostral pole a dense cluster of larger cells appears at the border with 10N. These cells are probably the ones that react for tyrosine hydroxylase (see Chapter 33).

### Prepositus and Interpositus Nuclei

The prepositus nucleus (Pr) succeeds the intercalated nucleus rostrally and displays a light AChE core surrounded by a region of greater reactivity (Figures 8.25–8.31). A distinct cluster of large cells well-stained for Nissl is found in the ventromedial tip of the Pr. The Pr is bordered medially by the oral dorsal paramedian and laterally by the interpositus nucleus (IPO) (Figures 8.26–8.30). Rostrally, Pr is succeeded by the AChE-dense region found immediately caudal and medial to the abducens nucleus. This AChE-positive region may correspond to the pontine paramedian reticular nucleus involved in horizontal gaze. Dorsal to the 10N, Olszewski and Baxter outlined IPO to separate Pr from the medial vestibular nucleus. Dorsal and rostral to the oral pole of Pr the supragenual nucleus can be detected by medium AChE reactivity.

Neurokinin (Covenas et al., 2003) and met-enkephalin (Covenas et al., 2004) immunoreactivities have been shown in the human Pr.

### Cribriform Nucleus

The cribriform nucleus (Crb) was identified by Paxinos and Huang (1995) as the area lateral to the solitary nucleus and medial to the dorsal column nuclei and spinal vestibular nucleus. This area is generally AChE-positive while characteristically perforated by AChE-negative fibers (Figures 8.21–8.25).

### Pontine Nuclei

The pontine nuclei (Pn) attain their maximal relative size in the human, nearly throttling the dorsal pontine tegmentum. Their outposts are distinguishable by the intense AChE reactivity of cell bodies and neuropil. As in other species, their main mass is found below the medial lemniscus. However, in the human, unlike the rat, there are pontine-like nuclei encircling and bisecting the rostral hindbrain. The pontobulbar nucleus (PnB) lies outside the inferior cerebellar peduncle and appears

caudally at the rostral pole of the external cuneate nucleus, presenting a triangular profile at this level (Figures 8.24, 8.25). At more rostral levels, the pontobulbar nucleus spreads to engulf this peduncle laterally and ventrally. Further rostrally, it is broken up into large islands in the ventrolateral aspects of the medulla (Figures 8.26–8.31). These islands are intermingled with the vestibular division of the vestibulocochlear nerve. The nuclei pararaphales (PaR) constitute two paramedian chains of islands of pontine-like cells that bisect the medulla at rostral levels (Figure 8.29) (see also Olszewski and Baxter, 1954).

The reticular tegmental nucleus (RtTg) is located close to the midline above the medial lemniscus. It is found immediately rostral to the exiting sixth nerve and it is replaced by MnR rostrally (Figures 8.35–8.45).

RtTg consists of many clusters of cells usually engulfed in AChE-reactive neuropil. Some cell clusters are associated with weak reactivity, though the cell bodies are positive. The cells are distinguishable from those of the pontine nuclei because they are larger and stain more intensely in Nissl preparations.

## Red Nucleus

The red nucleus is found at the level of the substantia nigra as a sphere encapsulated within the ascending superior cerebellar peduncle (Figures 8.55–8.64). At the level of the oculomotor nucleus, oculomotor nerve fibers run along the surface of the red nucleus (Onodera and Hicks, 2009).

In humans, the red nucleus consists of a magnocellular part (RMC) and a parvocellular part (RPC). RMC neurons are found in a variety of sizes: giant, large, medium, and small (Sobel, 1977). The number of giant-to-large-sized neurons is about 150–200 (Nathan and Smith, 1982). In quadrupedal animals, such as the rat and cat, red nucleus consists mainly of the RMC (ten Donkelaar, 1988).

A large number of cells in the red nucleus are multipolar and contain ferric iron pigment. These are assumed to be ectopically placed cells of the parabrachial pigmented nucleus, or of the caudal linear nucleus. At rostral levels, the fasciculus retroflexus penetrates the red nucleus, separating a dorsomedial portion. The dorsomedial portion displays higher AChE reactivity. Immunohistochemical studies revealed the presence of parkin (Parkinson disease related protein) (Zarate-Lagunes et al., 2001), somatostatin receptors (Selmer et al., 2000), as well as P2Y(1) purinergic receptor (Moore et al., 2000) in the red nucleus of the human. The nucleus is relatively large and current resolution of MRI and PET scans allows depiction of the red nucleus in the brain of the conscious human. For the connections of the red nucleus, see Chapter 15.

## Cerebral Peduncle

We followed the nomenclature of Covenas et al. (2004) for naming the components of the cerebral peduncle (cp), as corticospinal fibers (csp) and corticobulbar fibers (cbu) in our diagrams.

## CONCLUSION

This overview presents a classification of the human brainstem structures, including most of neuronal cell groups in the human brainstem. The most significant conclusion of this overview is a glaring structural similarity of brainstem across species reflected by an impressive number of homologies recognized between the brainstem of the human and that of other animals. While it can be hypothesized that there are human homologs to nearly every nucleus identified in the rat brainstem, species differences and even strain differences occur, and this compels us to establish homologies not by extrapolation but by direct observation of human tissue.

Functional mechanisms of the human brainstem, on the other hand, remain hidden in connections, chemoarchitecture, and physiology of neuronal groups. These characteristics are emerging from encouraging non-invasive imaging studies and expanding creative application of chemical analysis of the human brain. At that, a comparative structural plan of the brainstem fundamental to interpret, convey, and compare these findings is needed.

## Acknowledgment

Supported by an NHMRC Australia Fellowship to G Paxinos (Grant #568605). The authors thank Reuben Png for construction of figures.

## References

- Allien AM, McKinley MJ, Paxinos G, Oldfield BL, Mendelsohn EAO: Angiotensin II receptors in the human nervous system. In Paxinos G, Mendelsohn EAO, editors: *Receptors in the Human Nervous System*, San Diego, 1991, Academic Press, pp 190–192.
- Allien AM, Siew YC, Clevers J, McKinley ML, Paxinos G, Mendelsohn EAO: Localization and characterization of angiotensin II receptor binding and angiotensin converting enzyme in the human medulla oblongata, *J Comp Neurol* 269: 249–M4, 1988.
- Arango V, Ruggiero DA, Callaway JL, Anwar M, Reis DL, Mann JJ: Catecholamine neurons in the ventrolateral medulla and nucleus of the solitary tract in the human, *J Comp Neurol* 273:224–240, 1988.
- Austin MC, Rhodes JL, Lewis DA: Differential distribution of corticotropin-releasing hormone immunoreactive axons in monoaminergic nuclei of the human brainstem, *Neuropsychopharmacology* 17:326–341, 1997.
- Austin MC, Weikel JA, Arango V, Mann JJ: Localization of serotonin 5-HT1A receptor mRNA in neurons of the human brainstem, *Synapse* 18:276–279, 1994.



- Baizer JS, Baker JF, Haas K, Lima R: Neurochemical organization of the nucleus paramedianus dorsalis in the human, *Brain Res* 1176:45–52, 2007.
- Bagó AG, Dimitrov E, Saunders R, Seress L, Palkovits M, Usdin TB, Dobolyi A: Parathyroid hormone 2 receptor and its endogenous ligand tuberoinfundibular peptide of 39 residues are concentrated in endocrine, viscerosensory and auditory brain regions in macaque and human, *Neuroscience* 162:128–147, 2009.
- Baker KG, Halliday GM, Halasz P, Hornung JP, Geffen LB, Cotton RG, Törk I: Cytoarchitecture of serotonin-synthesizing neurons in the pontine tegmentum of the human brain, *Synapse* 7:301–320, 1991a.
- Baker KG, Halliday GM, Hornung JP, Geffen LB, Cotton RG, Törk I: Distribution, morphology and number of monoamine-synthesizing and substance P-containing neurons in the human dorsal raphe nucleus, *Neuroscience* 42:757–775, 1991b.
- Baker KG, Halliday GM, Törk I: Cytoarchitecture of the human dorsal raphe nucleus, *J Comp Neurol* 301:147–161, 1990.
- Bandler R, Carrive P, Zhang SP: Integration of somatic and autonomic reactions within the midbrain periaqueductal grey: viscerotopic, somatotopic and functional organization, *Prog Brain Res* 87:269–305, 1991.
- Becker LE, Zhang W: Vagal nerve complex in normal development and sudden infant death syndrome, *Canadian J Neurol Sci* 23:24–33, 1996.
- Beitz AJ: The midbrain periaqueductal gray in the rat. I. Nuclear volume, cell number, density, orientation, and regional subdivisions, *J Comp Neurol* 237:445–459, 1985.
- Benarroch EE, Schmeichel AM: Immunohistochemical localization of the angiotensin II type 1 receptor in human hypothalamus and brainstem, *Brain Res* 812:292–296, 1998.
- Benarroch EE, Schmeichel AM, Dugger BN, Sandroni P, Parisi JE, Low PA: Dopamine cell loss in the periaqueductal gray in multiple system atrophy and Lewy body dementia, *Neurology* 73:106–112, 2009.
- Benarroch EE, Smithson IL: Distribution and relationships of neuropeptide Y and NADPH-diaphorase in human ventrolateral medulla oblongata, *J Auton Nerv Syst* 62:143–146, 1997.
- Benarroch EE, Smithson IL, Low PA, Parisi JE: Depletion of catecholaminergic neurons of the rostral ventrolateral medulla in multiple systems atrophy with autonomic failure, *Ann Neurol* 43:149–151, 1998.
- Benarroch EE, Smithson IL, Low PA: Localization and possible interactions of catecholamine- and NADPH-diaphorase neurons in human medullary autonomic regions, *Brain Res* 684:215–220, 1995.
- Berman AL: *The Brainstem of the Cat: A Cytoarchitectonic Atlas with Stereotaxic Coordinates*, Madison, 1968, University of Wisconsin Press.
- Biaggioni I, Whetsell WO, Jobe J, Nadeau JH: Baroreflex failure in a patient with central nervous system lesions involving the nucleus tractus solitarius, *Hypertension* 23:491–495, 1994.
- Bittar RG, Nandi D, Carter H, Aziz TZ: Somatotopic organization of the human periventricular gray matter, *J Clin Neurosci* 12:240–241, 2005.
- Blessing WW, Gai WP: Caudal pons and medulla oblongata. In Bloom FE, Björklund A, Hökfelt T, editors: *The Primate Nervous System*, Amsterdam. Part I, 1997, Elsevier, pp 139–215.
- Bogerts B: A brainstem atlas of catecholamine neurons in man using melanin as a natural marker, *J Comp Neurol* 197:63–80, 1981.
- Borostyánkoi-Baldauf Z, Herczeg L: Parcellation of the human pre-tectal complex: a chemoarchitectonic reappraisal, *Neuroscience* 110:527–540, 2002.
- Bowman JP, Sladek JR: Morphology of the inferior olivary complex of the rhesus monkey (*Macaca mulatta*), *J Comp Neurol* 152:299–316, 1973.
- Braak H: Über die kerngebiete des menschlichen hirnstammes. I. Oliva inferior, *Nucleus conterminalis und Nucleus vermiformis Corporis restiformis*, *Z Zellforsch Mikrosk Anat* 105:442–456, 1970.
- Braak H: Über die kerngebiete des menschlichen hirnstammes. IV. Der Nucleus reticularis lateralis und seine satelliten, *Z Zellforsch Mikrosk Anat* 122:145–159, 1971.
- Bratincsák A, Kovács ZI, Palkovits M: Direct neuronal projection from a brainstem thermosensitive cell group to the preoptic thermoregulatory center, *Neuroscience* 156:966–972, 2008.
- Brodal A, Gogstad AC: Afferent connections of the paramedian reticular nucleus of the medulla oblongata in the cat. An experimental study, *Acta Anat* 30:133–151, 1957.
- Brodal P, Brodal A: The olivocerebellar projection in the monkey. Experimental studies with the method of retrograde tracing of horseradish peroxidase, *J Comp Neurol* 239:163–175, 1981.
- Bruce A: On the dorsal or so-called sensory nucleus of the glossopharyngeal nerve and on the nuclei of the trigeminal nerve, *Brain* 21:383–387, 1898.
- Butcher LL, Talbot K: Acetylcholinesterase in rat nigra-neostriatal neurons: experimental verification and evidence for cholinergic-dopaminergic interactions in the substantia nigra and caudate-putamen complex. In Butcher LL, editor: *Cholinergic-Monoaminergic Interactions in the Brain*, New York, 1978, Academic Press, pp 25–95.
- Büttner-Ennever JA, Buttner U, Cohen B, Baumgartner G: Vertical gaze paralysis and the rostral interstitial nucleus of the medial longitudinal fasciculus, *Brain* 105:125–149, 1982.
- Büttner-Ennever JA, Buttner U: A cell group associated with vertical eye movements in the rostral mesencephalic reticular formation of the monkey, *Brain Res* 151:31–47, 1978.
- Büttner-Ennever JA, Horn AKE: Reticular formation: eye movements, gaze, and blinks. In Paxinos G, Mai JK, editors: *The Human Nervous System*, ed 2, San Diego, 2004, Elsevier, pp 479–510.
- Carpentier V, Vaudry H, Laquerriere A, Tayot J, Leroux P: Distribution of somatostatin receptors in the adult human brainstem, *Brain Res* 734:135–148, 1996a.
- Carpentier V, Vaudry H, Maet E II, Laquerriere A, Tayot J, Leroux P: Anatomical distribution of somatostatin receptors in the brainstem of the human fetus, *Neuroscience* 73:865–879, 1996b.
- Carpentier V, Vaudry H, Mallet E, Tayot J, Laquerriere A, Leroux P: Ontogeny of somatostatin binding sites in respiratory nuclei of the human brainstem, *J Comp Neurol* 381:461–472, 1997.
- Carpentier V, Vaudry H, Mallet E, Laquerriere A, Leroux P: Increased density of somatostatin binding sites in respiratory nuclei of the brainstem in sudden infant death syndrome, *Neuroscience* 86:159–166, 1998.
- Carrive P, Bandler R, Dampney RA: Somatic and autonomic integration in the midbrain of the unanesthetized decerebrate cat: a distinctive pattern evoked by excitation of neurons in the sub-tentorial portion of the midbrain periaqueductal grey, *Brain Res* 483:251–258, 1989.
- Carrive P, Paxinos G: The supraoculomotor cap: a region revealed by NADPH diaphorase histochemistry, *Neuroreport* 5:2257–2260, 1994.
- Chan-Palay V: The paratrigeminal nucleus. I. Neurons and synaptic organization, *Neurocytology* 7:405–418, 1978a.
- Chan-Palay V: The paratrigeminal nucleus. II. Identification and interrelations of catecholamine axons, indoleamine axons, and substance P immunoreactive cells in the neuropil, *Neurocytology* 7:419–442, 1978b.
- Cheng G, Zhu H, Zhou X, Qu J, Ashwell KW, Paxinos G: Development of the human nucleus of the solitary tract: a cyto- and chemo-architectural study, *Auton Neurosci* 128:76–95, 2006.
- Counihan TJ, Landwehrmeyer GB, Standaert DG, Kosinski CM, Scherzer CR, Daggett LP, Veliçelebi G, Young AB, Penney JB Jr: Expression of N-methyl-D-aspartate receptor subunit mRNA in

- the human brain: mesencephalic dopaminergic neurons, *J Comp Neurol* 390:91–101, 1998.
- Cordero ME, Rodriguez A, Torres R, Valenzuela CY: Human Raphe Magnus Nucleus: a morphometric Golgi-Cox study with emphasis on sex differences, *Brain Res Dev Brain Res* 131:85–92, 2001.
- Cotton RG, Törk I: Cytoarchitecture of serotonin-synthesizing neurons in the pontine tegmentum of the human brain, *Synapse* 7:301–320, 1991.
- Coveñas R, Martín F, Belda M, Smith V, Salinas P, Rivada E, Diaz-Cabiale Z, Narvaez JA, Marcos P, Tramu G, Gonzalez-Baron S: Mapping of neurokinin-like immunoreactivity in the human brainstem, *BMC Neurosci* 4:3, 2003.
- Coveñas R, Martín F, Salinas P, Rivada E, Smith V, Aguilar LA, Díaz-Cabiale Z, Narvaez JA, Tramu G: An immunocytochemical mapping of methionine-enkephalin-Arg(6)-Gly(7)-Leu(8) in the human brainstem, *Neuroscience* 128:843–859, 2004.
- Damier P, Hirsch EC, Agid Y, Graybiel AM: The substantia nigra of the human brain. I. Nigrosomes and the nigral matrix, a compartmental organization based on calbindin D (28K) immunohistochemistry, *Brain* 122:1421–1436, 1999a.
- Damier P, Hirsch EC, Agid Y, Graybiel AM: The substantia nigra of the human brain. II. Patterns of loss of dopamine-containing neurons in Parkinson's disease, *Brain* 122:1437–1448, 1999b.
- Del Fiacco M, Dessi ML, Levanti MC: Topographical localization of substance P in the human postmortem brainstem. An immunohistochemical study in the newborn and adult tissue, *Neuroscience* 12:591–611, 1984.
- Del Fiacco M, Quartu M, Sera MP, Follesa P, Lai ML, Bachis A: Topographical localization of glial cell line-derived neurotrophic factor in the human brainstem: an immunohistochemical study of prenatal, neonatal and adult brains, *J Chem Neuroanat* 23:29–48, 2002.
- Duncan JR, Paterson DS, Kinney HC: The development of nicotinic receptors in the human medulla oblongata: inter-relationship with the serotonergic system, *Auton Neurosci* 144:61–75, 2008.
- Eden AR, Chandross KL, Laitman JL, Gannon PJ: The salivatory nuclei of *Macaca fascicularis*, *Soc Neurosci Abstr* 142:1318, 1988.
- Ferraro JA, Minckler J: The human lateral lemniscus and its nuclei. The human auditory pathways: a quantitative study, *Brain Language* 4:277–294, 1977.
- Fix JD: A melanin-containing nucleus associated with the superior cerebellar peduncle in man, *J Hirnforsch* 21:429–436, 1980.
- Filiano JJ, Choi JC, Kinney HC: Candidate cell populations for respiratory chemosensitive fields in the human infant medulla, *J Comp Neurol* 293:448–465, 1990.
- Filiano JJ, Kinney HC: Arcuate nucleus hypoplasia in the sudden infant death syndrome, *J Neuropath Exp Neurol* 51:394–403, 1992.
- Fonseca MI, Ni YG, Dunning DD, Milei R: Distribution of serotonin 2A, 2C and 3 receptor mRNA in spinal cord and medulla oblongata, *Brain Res Mol Brain Res* 89:11–19, 2001.
- Franklin KBJ, Paxinos G: *The Mouse Brain in Stereotaxic Coordinates*, ed 3, San Diego, 2008, Academic Press.
- Fredericks CA, Giolli RA, Blanks RHI, Sadun AA: The human accessory optic system, *Brain Res* 454:116–122, 1988.
- Fu Y, Tvrdik P, Makki N, Palombi O, Machold R, Paxinos G, Watson C: The precerebellar linear nucleus in the mouse defined by connections, immunohistochemistry, and gene expression, *Brain Res* 1271:49–59, 2009.
- Fulwiler CE, Saper CB: Subnuclear organization of the efferent connections of the parabrachial nucleus in the rat, *Brain Res Rev* 7:229–259, 1984.
- Gai WP, Blessing WW: Nitric oxide synthesizing neurons in the central subnucleus of the nucleus tractus solitarius in humans, *Neurosci Lett* 204:189–192, 1996.
- Gau R, Sévoz-Couche C, Laguzzi R, Hamon M, Bernard JF: Inhibition of cardiac baroreflex by noxious thermal stimuli: a key role for lateral paragigantocellular serotonergic cells, *Pain* 146:315–324, 2009.
- Gibb WR: Melanin, tyrosine hydroxylase, calbindin and substance P in the human midbrain and substantia nigra in relation to nigrostriatal projections and differential neuronal susceptibility in Parkinson's disease, *Brain Res* 581:283–291, 1992.
- Gioia M, Rodella L, Petruccioli MG, Bianchi R: The cytoarchitecture of the adult human parabrachial nucleus: a Nissl and Golgi study, *Arch Histol Cytol* 63:411–424, 2000.
- Glass M, Dragunow M, Faull RL: Cannabinoid receptors in the human brain: a detailed anatomical and quantitative autoradiographic study in the fetal, neonatal and adult human brain, *Neuroscience* 77:299–318, 1997.
- Goncharuk V, Jhamandas JH: Neuropeptide FF2 receptor distribution in the human brain. An immunohistochemical study, *Peptides* 29:1544–1553, 2008.
- Guyenet PG, Haselton JR, Sun MK: Sympathoexcitatory neurons of the rostroventrolateral medulla and the origin of the sympathetic vasomotor tone, *Prog Brain Res* 81:105–116, 1989.
- Gwyn DG, Leslie RA, Hopkins DA: Observation on the afferent and efferent organization of the vagus nerve and the innervation of the stomach in the squirrel monkey, *J Comp Neurol* 239:163–175, 1985.
- Halliday GM, Törk I: Comparative anatomy of the ventromedial mesencephalic tegmentum in the rat, cat, monkey and human, *J Comp Neurol* 252:423–445, 1986.
- Halliday GM, Li YW, Blumbergs PC, Joh TH, Cotton RG, Howe PR, Blessing WW, Geffen LB: Neuropathology of immunohistochemically identified brainstem neurons in Parkinson's disease, *Ann Neurol* 27:373–385, 1990.
- Halliday GM, Li YW, Joh TH, Cotton RG, Howe PRC, Geffen L, Blessing WW: The distribution of substance P-like immunoreactive neurons in the human medulla oblongata, colocalization with monoamine synthesizing neurons, *Synapse* 2:353–370, 1988a.
- Halliday GM, Li YW, Joh TH, Cotton RG, Howe PRC, Geffen LB, Blessing WW: Distribution of monoamine synthesizing neurons in the human medulla oblongata, *J Comp Neurol* 273:301–317, 1988b.
- Halliday GM, Li YW, Oliver JR, Joh TH, Cotton RG, Howe PRC, Geffen L, Blessing WW: The distribution of neuropeptide Y-like immunoreactive neurons in the human medulla oblongata, *Neuroscience* 26:179–191, 1988c.
- Halliday GM, Törk I: Comparative anatomy of the ventromedial mesencephalic tegmentum in the rat, cat, monkey and human, *J Comp Neurol* 252:423–445, 1986.
- Hammer KH, Klingberg F: Active avoidance is permanently abolished after lesions of the nucleus interpeduncularis in rat, *Biomed Biochim Acta* 49:489–497, 1990.
- Hayakawa I, Zyo K: Comparative cytoarchitectonic study of Gudden's tegmental nuclei in some mammals, *J Comp Neurol* 216:233–244, 1983.
- Heimer L, Wilson RD: The subcortical projections of the allocortex: similarities in the neural associations of the hippocampus, the piriform cortex, and the neocortex. In Santini M, editor: *"Golgi Centennial Symposium"*, New York, 1975, Raven Press, pp 177–193.
- Herbert H, Saper CB: Cholecystokinin-, galanin-, and corticotropin-releasing factor-like immunoreactive projections from the nucleus of the solitary tract to the parabrachial nucleus in the rat, *J Comp Neurol* 293:581–598, 1990.
- Herkenham M: Anesthetics and the habenulo-interpeduncular system: selective sparing of metabolic activity, *Brain Res* 210:461–466, 1991.

- Hermann GE, Holmes GM, Rogers RC, Beattie MS, Bresnahan JC: Descending spinal projections from the rostral gigantocellular reticular nuclei complex, *J Comp Neurol* 455:210–221, 2003.
- Herrick CJ: *"An Introduction to Neurology"*, ed 3, Philadelphia, 1922, W.B. Saunders.
- Hilbig H, Bidmon HJ, Zilles K, Busecke K: Neuronal and glial structures of the superficial layers of the human superior colliculus, *Anat Embryol* 200:103–115, 1999.
- Holstege G, Kuypers HGJM: Proprietary fiber connections to the trigeminal, facial and hypoglossal motor nuclei. I. An anterograde degeneration study in the cat, *Brain* 100:239–264, 1977.
- Holstege G, Tan J: Projections from the red nucleus and surrounding areas to the brainstem and spinal cord in the cat. An HRP and autoradiographical tracing study, *Behav Brain Res* 28:33–57, 1988.
- Horn AK, Eberhorn A, Härtig W, Ardeleanu P, Messoudi A, Büttner-Ennever JA: Periocular motor cell groups in monkey and man defined by their histochemical and functional properties: reappraisal of the Edinger-Westphal nucleus, *J Comp Neurol* 507:1317–1335, 2008.
- Horn AK, Schulze C, Radtke-Schuller S: The Edinger-Westphal nucleus represents different functional cell groups in different species, *Ann N Y Acad Sci* 1164:45–50, 2009.
- Hornung JP: The human raphe nuclei and the serotonergic system, *J Chem Neuroanat* 26:331–343, 2003.
- Hornung JP: Raphe nuclei. In Paxinos G, Mai JK, editors: *"The Human Nervous System"*, ed 2, San Diego, 2004, Elsevier, pp. 4735–436
- Huang XF, Paxinos G, Halasz P, McRitchie D, Törk I: Substance P- and tyrosine hydroxylase-containing neurons in the human dorsal motor nucleus of vagus nerve, *J Comp Neurol* 335:109–122, 1993.
- Huang XF, Törk I, Paxinos G: Dorsal motor nucleus of vagus nerve: a cyto- and chemoarchitectonic study in the human, *J Comp Neurol* 330:158–182, 1993.
- Huang XF, Törk I, Halliday GM, Paxinos G: The dorsal, posterodorsal, and ventral tegmental nuclei: a cyto- and chemoarchitectonic study in the human, *J Comp Neurol* 318:117–137, 1992.
- Hubscher CH, Johnson RD: Responses of medullary reticular formation neurons to input from the male genitalia, *J Neurophysiol* 76:2474–2482, 1996.
- Hurd YL, Fagergren P: Human cocaine- and amphetamine-regulated transcript (CART) mRNA is highly expressed in limbic- and sensory-related brain regions, *J Comp Neurol* 425:583–598, 2000.
- Hyde TM, Knable MB, Murray AM: Distribution of dopamine D1-D4 receptor subtypes in human dorsal vagal complex, *Synapse* 24:224–232, 1996.
- Ikemoto K, Nagatsu I, Ito S, King RA, Nishimura A, Nagatsu T: Does tyrosinase exist in neuromelanin-pigmented neurons in the human substantia nigra? *Neurosci Lett* 253:198–200, 1998.
- Johnson RD, Hubscher CH: Brainstem microstimulation differentially inhibits pudendal motoneuron reflex inputs, *Neuroreport* 9:341–345, 1998.
- Kasashima S, Muroishi Y, Futakuchi H, Nakanishi I, Oda Y: In situ mRNA hybridization study of the distribution of choline acetyltransferase in the human brain, *Brain Res* 806:8–15, 1998.
- King GW: Topology of ascending brainstem projections to nucleus parabrachialis in the cat, *J Comp Neurol* 191:615–638, 1980.
- Kitahama K, Pearson J, Denroy L, Kopp N, Ulrich J, Naeda I, Jouvét N: Adrenergic neurons in human brain demonstrated by immunohistochemistry with antibodies to phenylethanolamine-N-methyltransferase (PNMT): discovery of a new group in the nucleus tractus solitarius, *Neurosci Lett* 53:303–308, 1985.
- Kitahama K, Sakamoto N, Jouvét A, Nagatsu, I, Pearson J: Dopamine-beta-hydroxylase and tyrosine hydroxylase immunoreactive neurons in the human brainstem, *J Chem Neuroanat* 10:137–146, 1996.
- Klimek V, Stockmeier C, Overholser J, Meltzer HY, Kalka S, Dilley G, Ordway GA: Reduced levels of norepinephrine transporters in the locus coeruleus in major depression, *J Neurosci* 17:8451–8458, 1997.
- Koelle GB, Friedenwald JS: A histochemical method for localizing cholinesterase activity, *Proc Soc Exp Biol Med* 70:617–622, 1949.
- Koutcherov Y, Ashwell KWA, Mai JK, Paxinos G: Organization of the human paraventricular hypothalamic nucleus, *J Comp Neurol* 423:299–318, 2000.
- Krammer EB, Rath I, Lischka ME: Somatotopic organization of the hypoglossal nucleus: a HRP study in the rat, *Brain Res* 170:533–537, 1979.
- Krettek JE, Price JL: A description of the amygdaloid complex in the rat and cat with observations on intra-amygdaloid axonal connections, *J Comp Neurol* 178:225–280, 1978.
- Kulesza RJ Jr: Cytoarchitecture of the human superior olivary complex: nuclei of the trapezoid body and posterior tier, *Hear Res* 241:52–63, 2008.
- Kuypers HGJM: Central cortical projections to motor and somatosensory cell groups, *Brain* 83:161–184, 1960.
- Kuypers HGJM, Turek JD: The distribution of the cortical fibers within the nuclei cuneatus and gracilis in the cat, *J Anat* 98:143–160, 1964.
- Loewy AD: Central autonomic pathways. In Loewy AD, Spyer KM, editors: *"Central Regulation of Autonomic Function"*, Oxford, 1990, Oxford University Press, pp 88–103.
- Mason P: Contributions of the medullary raphe and ventromedial reticular region to pain modulation and other homeostatic functions, *Annu Rev Neurosci* 24:737–777, 2001.
- Laerle LK: A Golgi study of cell morphology in the deep layers of the human superior colliculus, *J Hirnforsch* 24:297–306, 1983.
- de Lacalle S, Saper CB: Calcitonin gene-related peptide like immunoreactivity marks putative viscerosensory pathways in human brain, *Neuroscience* 100:115–130, 2000.
- Lavezzi AM, Ottaviani G, Rossi L, Matturri L: Cytoarchitectural organization of the parabrachial/Kölliker-Fuse complex in man, *Brain Dev* 26:316–320, 2004.
- Lerath L: The red nucleus in the mice, monkey and man, *Indian J Physiol Pharmacol* 8:143–148, 1964.
- Lima D, dan Almeida A: The medullary dorsal reticular nucleus as a proprioceptive centre of the pain control system, *Prog Neurobiol* 66:81–108, 2002.
- Lynn RB, Hyde TM, Cooperman RR, Miselis RR: Distribution of bombesin-like immunoreactivity in the nucleus of the solitary tract and dorsal motor nucleus of the rat and human: colocalization with tyrosine hydroxylase, *J Comp Neurol* 369:552–570, 1996.
- Macchi V, Porzionato A, Belloni AS, Stecco C, Parenti A, De Caro R: Immunohistochemical mapping of adrenomedullin in the human medulla oblongata, *Peptides* 27:1397–1404, 2006.
- Mai JK, Assheuer J, Paxinos G: *"Atlas of the Human Brain"*, San Diego, 1997, Academic Press.
- Marani E, Voogd J, Bockee A: Acetylcholinesterase staining in subdivisions of the cats inferior olive, *J Comp Neurol* 174:209–226, 1977.
- Marcyniuk NB, Mann DMA, Yates PO: The topography of cell loss from locus coeruleus in Alzheimer's disease, *J Neurol Sci* 76:335–345, 1986a.
- Marcyniuk NB, Mann DM, Yates EO: Loss of nerve cells from locus coeruleus in Alzheimer's disease is topographically arranged, *Neurosci Lett* 64:247–252, 1986b.
- Martino R, Terrault N, Ezerzer E, Mikulis D, Diamant NE: Dysphagia in a patient with lateral medullary syndrome: insight into the central control of swallowing, *Gastroenterology* 121:420–426, 2001.
- Matturri L, Minoli I, Lavezzi AM, Cappellin A, Ramos S, Rossi L: Hypoplasia of medullary arcuate nucleus in unexpected late fetal



- death (stillborn infants): a pathologic study, *Pediatrics* 109:E43, 2002.
- McKenzie JC, Juan YW, Thomas CR, Berman NE, Klein RM: Atrial natriuretic peptide-like immunoreactivity in neurons and astrocytes of human cerebellum and inferior olivary complex, *J Histochem Cytochem* 49:1453–1467, 2001.
- McRitchie DA, Törk I: The internal organization of the human solitary nucleus, *Brain Res Bull* 31:171–193, 1993.
- McRitchie DA, Törk I: Distribution of substance P-like immunoreactive neurons and terminals throughout the nucleus of the solitary tract in the human brainstem, *J Comp Neurol* 343:83–101, 1994.
- Meessen H, Olszewski J: "A Cytoarchitectonic Atlas of the Rhombencephalon of the Rabbit.", New York, 1949, Karger.
- Mehler WR: Observations on the connectivity of the parvicellular reticular formation with respect to a vomiting center, *Brain Behav Evol* 23:63–80, 1983.
- Mehler WR: Some neurological species differences—a poster, *Ann N Y Acad Sci* 167:424–468, 1969.
- Mehler WR: Central pain and the spinothalamic tract. In Bonica JJ, editor: "Pain", New York, 1974a, Raven Press, pp 88–103.
- Mehler WR: A comparative study of the cells of origin of cerebellar afferents in the rat, cat, monkey studied with horseradish peroxidase technique. II. The vestibular nuclear complex, *Anat Rec* 187:653, 1974b.
- Mehler WR: A comparative study of cells of origin of cerebellar afferents in the rat, cat, and monkey studied with HRP technique: II. The vestibular nuclear complex, *Anat Rec* 187:653, 1977.
- Mehler WR, Rubertone J: Anatomy of the vestibular nucleus complex. In Paxinos G, editor: *The Rat Nervous System*, vol 2, Orlando, 1986, Academic Press, pp 88–103.
- Meszáros I, Gajewska S, Tarchalska-Krynska B: Habenulo-interpeduncular lesions: The effects on pain sensitivity, morphine analgesia and open-field behavior in rats, *J Pharmacol Pharm* 37:469–477, 1985.
- Mikail Y, Ahmed YY: Outline of the arcuate nucleus of the human medulla oblongata, *Acta Anat* 92:285–291, 1975.
- Moore D, Chambers J, Waldvogel H, Faull R, Emson P: Regional and cellular distribution of the P2Y(1) purinergic receptor in the human brain: striking neuronal localisation, *J Comp Neurol* 421:374–384, 2000.
- de Mota N, Iturriz X, Claperon C, Bodineau L, Fassot C, Roques BP, Palkovits M, Llorens-Cortés C: Human brain aminopeptidase A: biochemical properties and distribution in brain nuclei, *J Neurochem* 106:416–428, 2008.
- Nageotte J: The pars intermedia of nervus intermedius of Wrisberg, and the bulbopontine gustatory nucleus in man, *Rev Neurol Psychiatry (Edinburgh)* 4:473–488, 1906.
- Nathan PW, Smith MC: The rubrospinal and central tegmental tracts in man, *Brain* 105:223–269, 1982.
- Ni L, Miller Jonakait G: Development of substance P-containing neurons in the central nervous system in mice: an immunocytochemical study, *J Comp Neurol* 275:493–510, 1988.
- Nomura H, Shiosaka S, Tohyama M: Distribution of substance P-like immunoreactive structures in the brainstem of the adult human brain: an immunocytochemical study, *Brain Res* 404:365–370, 1987.
- Norgren R: Gustatory system. In Paxinos G, Mai JK, editors: "The Human Nervous System", ed 2, San Diego, 1990, Academic Press, pp 1171–1191.
- Ohm T, Braak JW: The pigmented subpeduncular nucleus (nucleus subpeduncularis pigmentosus) in the human brain. Normal morphology and pathological changes in Alzheimer's disease, *Neuroscience* 22:S785, 1987.
- Olszewski J, Baxter D: "Cytoarchitecture of the Human Brainstem", Philadelphia, 1954, J.B. Lippincott.
- Ono S, Takahashi K, Jinnai K, Kanda E, Fukuoka Y, Kurisaki H, Mitake S, Inagaki T, Yamano T, Shimizu N, Nagao K: Loss of catecholaminergic neurons in the medullary reticular formation in myotonic dystrophy, *Neurology* 51:1121–1124, 1988.
- Onodera S, Hicks TP: A comparative neuroanatomical study of the red nucleus of the cat, macaque and human, *PLoS One* 4:e6623, 2009.
- Ordway GA, Stockmeier CA, Cason GW, Klimek V: Pharmacology and distribution of norepinephrine transporters in the human locus coeruleus and raphe nuclei, *J Neurosci* 17:1710–1719, 1997.
- Ostapoff EM, Johnson JJ, Albright BC: Medullary sources of projections to the kinesthetic thalamus in racoons: external and basal cuneate nuclei and cell groups X and Z, *J Comp Neurol* 267:231–252, 1988.
- Pandya DN, Rosene DL, Doolittle AM: Corticothalamic connections of auditory-related areas of the temporal lobe in the rhesus monkey, *J Comp Neurol* 345:447–471, 1994.
- Panigrahy A, Filiano JJ, Sleeper LA, Mandell F, Valdes-Dapena M, Krouse HF, Rava LA, White WF, Kinney HC: Decreased kainate receptor binding in the arcuate nucleus of the sudden infant death syndrome, *J Neuropathol Exp Neurol* 56:1253–1261, 1997.
- Panigrahy A, Filiano JJ, Sleeper LA, Mandell F, Valdes-Dapena M, Krouse HF, Rava LA, Foley E, White WF, Kinney HC: Decreased serotonergic receptor binding in rhombic lip-derived regions of the medulla oblongata in the sudden infant death syndrome, *J Neuropathol Exp Neurol* 59:377–384, 2000.
- Panigrahy A, Sleeper LA, Assmann S, Rava LA, White WF, Kinney HC: Developmental changes in heterogeneous patterns of neurotransmitter receptor binding in the human interpeduncular nucleus, *J Comp Neurol* 390:322–332, 1998.
- Papez JW: "Comparative Neurology", New York, 1929, Hadner.
- Paterson DS, Darnall R: 5-HT<sub>2A</sub> receptors are concentrated in regions of the human infant medulla involved in respiratory and autonomic control, *Auton Neurosci* 147:48–55, 2009.
- Pau KY, Yu JH, Lee CJ, Spies HG: Topographic localization of neuropeptide Y mRNA in the monkey brainstem, *Regul Pept* 75-76:145–153, 1998.
- Paxinos G: Evidence for the existence of a parvicellular nucleus medial to the parabrachial (PBG) nucleus, *Neurosci Lett, Suppl* 14:S276, 1983.
- Paxinos G: The microcellular tegmental nucleus (Mi), *Neurosci Lett, Suppl* 1-9:589, 1985.
- Paxinos G, Butcher LL: Organizational principles of the brain as revealed by choline acetyltransferase and acetyl cholinesterase distribution and projections. In Paxinos G, editor: "The Rat Nervous System", vol 1, San Diego, 1986, Academic Press, pp 487–521.
- Paxinos G, Huang XF: *Atlas of the Human Brainstem*, San Diego, 1995, Academic Press.
- Paxinos G, Huang XF, Petrides M, Toga AW: *The Rhesus Monkey Brain in Stereotaxic Coordinates*, ed 2, San Diego, 2009, Academic Press.
- Paxinos G, Huang XF, Petrides M, Toga AW: *The Rhesus Monkey Brain in Stereotaxic Coordinates*, ed 3, 2010, in BrainNavigator, Elsevier.
- Paxinos G, Törk L, Halliday G, Mehler WR: The human intermediate reticular nucleus (IRt), *Soc Neurosci Abstr* 14:1317, 1988.
- Paxinos G, Watson C: "The Rat Brain in Stereotaxic Coordinates", Sydney, 1982, Academic Press.
- Paxinos G, Watson C: "The Rat Brain in Stereotaxic Coordinates", ed 3, San Diego, 1998, Academic Press.
- Paxinos G, Watson C: "The Rat Brain in Stereotaxic Coordinates", ed 6, San Diego, 2007, Academic Press.
- Paxinos G, Watson C, Petrides M, Rosa MG, Tokuno H: *The Marmoset Brain in Stereotaxic Coordinates*, San Diego, 2012, Academic Press.
- Pearson AA: The roots of the facial nerve in the human embryos and fetuses, *J Comp Neurol* 87:139–159, 1947.

- Pearson J, Halliday G, Sakamoto N, and Michel JP: Catecholaminergic neurons. In Paxinos G, editor: *"The Human Nervous System"*, San Diego, 1990, Academic Press, pp 1023–1050.
- Petri S, Krampfl K, Dengler R, Buefler J, Weindl A, Arzberger T: Human GABA A receptors on dopaminergic neurons in the pars compacta of the substantia nigra, *J Comp Neurol* 452:360–366, 2002.
- Petrovicky P: Structure and incidence of Gudden's tegmental nuclei in some mammals, *Acta Anat* 80:273–286, 1973.
- Phillips JK, Goodchild AK, Dubey R, Sesiashvili E, Takeda M, Chalmers J, Pilowsky PM, Lipski J: Differential expression of catecholamine biosynthetic enzymes in the rat ventrolateral medulla, *J Comp Neurol* 432:20–34, 2001.
- Quartu M, Sera MP, Boi M, Ferretti MT, Lai ML, Del Fiacco M: Tissue distribution of Ret, GFRalpha-1, GFRalpha-2 and GFRalpha-3 receptors in the human brainstem at fetal, neonatal and adult age, *Brain Res* 1173:36–52, 2007.
- Richter EA, Norris BE, Fullerton BC, Levine RA, Kiang NY5: Is there a medial nucleus of the trapezoid body in humans? *Am J Anat* 168:157–166, 1983.
- Riley HA: *"An Atlas of the Basal Ganglia, Brainstem and Spinal Cord Based on Myelin-Stained Material"*, Baltimore, 1943, Williams and Wilkins.
- Rikard-Bell GC, Törk I, Sullivan C, Scheibner T: Distribution of substance P-like immunoreactive fibres and terminals in the medulla oblongata of the human infant, *Neuroscience* 34:133–148, 1990.
- Rub U, Del Tredici K, Schultz C, Thal DR, Braak E, Braak H: The autonomic higher order processing nuclei of the lower brainstem are among the early targets of the Alzheimer's disease—related cytoskeletal pathology, *Acta Neuropathol (Berl.)* 101:555–564, 2001.
- Rüb U, Jen JC, Braak H, Deler T: Functional neuroanatomy of the human premotor oculomotor brainstem nuclei: insights from postmortem and advanced in vivo imaging studies, *Exp Brain Res* 187:167–180, 2008.
- Ruggiero DA, Underwood MD, Mann JJ, Anwar M, Arango V: The human nucleus of the solitary tract: visceral pathways revealed with an "in vitro" postmortem tracing method, *J Auton Nerv Syst* 79:181–190, 2000.
- Sadjadpour K, Brodal A: The vestibular nuclei in man. A morphological study in the light of experimental findings in the cat, *J Hirnforsch* 10:299–323, 1968.
- Saper CB, German DC: Hypothalamic pathology in Alzheimer's disease, *Neurosci Lett* 74:364–370, 1987.
- Sasaki M, Shibata E, Tohyama K, Kudo K, Endoh J, Otsuka K, Sakai A: Monoamine neurons in the human brain stem: anatomy, magnetic resonance imaging findings, and clinical implications, *Neuroreport* 19:1649–1654, 2008.
- Satoda T, Takahashi O, Tashiro T, Matsushima R, Uemura-Sumi M, Mizuno N: Representation of the main branches of the facial nerve within the facial nucleus of the Japanese monkey (*Macaca fuscata*), *Neurosci Lett* 78:283–287, 1987.
- Satoh K, Tohyama M, Yamamoto I, Sakumoto I, Shimizu N: Noradrenaline innervation of the spinal cord studied by horseradish peroxidase method combined with monoamine oxidase staining, *Exp Brain Res* 223:175–186, 1977.
- Selmer IS, Schindler M, Humphrey PP, Waldvogel HJ, Faull RL, Emson PC: First localisation of somatostatin sst(4) receptor protein in selected human brain areas: an immunohistochemical study, *Brain Res Mol Brain Res* 82:114–125, 2000.
- Serrats J, Artigas F, Mengod G, Cortés R: GABAB receptor mRNA in the raphe nuclei: co-expression with serotonin transporter and glutamic acid decarboxylase, *J Neurochem* 84:743–752, 2003.
- Sexton PM, Paxinos G, Huang XF, Mendelsohn FA: In vitro autoradiographic localization of calcitonin binding sites in human medulla oblongata, *J Comp Neurol* 341:449–463, 1994.
- Smith D, Hill RG, Edvinsson L, Longmore J: An immunocytochemical investigation of human trigeminal nucleus caudalis: CGRP, substance P and 5-HT1D-receptor immunoreactivities are expressed by trigeminal sensory fibres, *Cephalalgia* 22:424–431, 2002.
- Sobel LI: The red nucleus of man and chimpanzee: a quantitative cytoarchitectural study. Master's Degree thesis, Albany Medical College. In Strominger RN, McGiffen JE, Strominger NL, Morphometric and experimental studies of the red nucleus in the albino rat., *Anat Rec* 21:420–428, 1977.
- Somana R, Walberg E: The cerebellar projection from the paratrigeminal nucleus in the cat, *Neurosci Lett* 15:49–54, 1979.
- Stromberg NL, Hurwitz JL: Anatomical aspects of the superior olivary complex, *J Comp Neurol* 170:485–491, 1976.
- Tajti J, Uddman R, Edvinsson L: Neuropeptide localization in the "migraine generator" region of the human brainstem, *Cephalalgia* 21:96–101, 2001.
- Ten Donkelaar HJ: Evolution of the red nucleus and rubrospinal tract, *Behav Brain Res* 28:920, 1988.
- Törk I: Anatomy of the serotonergic system. In Whitaker-Azmitia P, Peroutka SJ, editors: *"Neuropharmacology of Serotonin"*, New York, 1990, New York Academy of Sciences, pp 1–35.
- Trouth CO, Milis RM, Bernard DG, Pan Y, Whittaker JA, Archer PW: Cholinergic-opioid interactions at brainstem respiratory chemosensitive areas in cats, *Neurotoxicology* 14:459–467, 1993.
- Villanueva L, Bouhassira D, Bing Z, Le Bars D: Convergence of heterotopic nociceptive information onto subnucleus reticularis dorsalis neurons in the rat medulla, *J Neurophysiol* 60:980–1009, 1988.
- Villanueva L, Bouhassira D, Le Bars D: The medullary subnucleus reticularis dorsalis (SRD) as a key link in both the transmission and modulation of pain signals, *Brain Res* 873:131–134, 2000.
- von Gudden B: Über das corpus mammillare und die sogenannteschenkel des fornix, *Vers Dtsch Naturforsch, Magdeburg, Tagungsbls* 57:126, 1884.
- von Gudden B: Über das corpus mammillare und diesogenannteschenkel des fornix. In Grasbey H, editor: *"Berhard von Gudden's gesammelte und hinterlassene Abhandlungen"*, 1889, J. E Bergman, Weisbaden, pp 190–192.
- Walberg F: The lateral reticular nucleus of the medulla oblongata in mammals. A comparative-anatomical study, *J Comp Neurol* 96:283–337, 1952.
- Waldvogel HJ, Billinton A, White JH, Emson PC, Faull RL: Comparative cellular distribution of GABAA and GABAB receptors in the human basal ganglia: immunohistochemical colocalization of the alpha 1 subunit of the GABAA receptor, and the GABABR1 and GABABR2 receptor subunits, *J Comp Neurol* 470:339–356, 2004.
- Wallace MN: Lattices of high histochemical activity occur in the human, monkey, and cat superior colliculus, *Neuroscience* 25: 569–583, 1988.
- Westlund KN, Denney RM, Rose RM, Abels CW: Localization of distinct monoamine oxidase A and monoamine oxidase B cell populations in human brainstem, *Neuroscience* 25:439–456, 1988.
- Xu Y, Stokes AH, Freeman WM, Kumer SC, Vogt BA, Vrana KE: Tyrosinase mRNA is expressed in human substantia nigra, *Brain Res Mol Brain Res* 45:159–162, 1997.
- Yamada H, Ezure K, Manabe M: Efferent projections of inspiratory neurons of the ventral respiratory group. A dual labeling study in the rat, *Brain Res* 455:283–294, 1988.
- Yamaguchi K, Goto N, Honma K: Development of the human gigantocellular reticular nucleus: a morphometric study., *Acta Anat (Basel)* 150:191–197, 1994.



- Zarate-Lagunes M, Gu WJ, Blanchard V, Francois C, Muriel MR, Mouatt-Prigent A, Bonici B, Parent A, Hartmann A, Yelnik J, Boehme GA, Pradier L, Moussaoui S, Faucheux B, Raisman-Vozari R, Agid Y, Brice A, Hirsch EC: Parkin immunoreactivity in the brain of human and non-human primates: an immunohistochemical analysis in normal conditions and in Parkinsonian syndromes, *J Comp Neurol* 432:184–196, 2001.
- Zec N, Filiano JJ, Kinney HC: Anatomic relationships of the human arcuate nucleus of the medulla: a DiI-labeling study, *J Neuropath Exp Neurol* 56:509–522, 1997.
- Zec N, Kinney HC: Anatomic relationships of the human nucleus paragigantocellularis lateralis: a DiI labeling study, *Auton Neurosci* 89:110–124, 2001.
- Ziehen T: Centralnervensystem. In Eggerling V, editor: *Handbuch der Anatomie des Menschen*, vol 4, Jena, 1934, Fisher.
- Zhuo J, Moeller I, Jenkins T, Chai SY, Allen AM, Ohishi M, Mendelsohn FA: Mapping tissue angiotensin-converting enzyme and angiotensin AT1, AT2 and AT4 receptors, *J Hypertens* 16: 2027–2037, 1998.